

This journal article contains language that may not fall within the scope of FDA clearance of Lipogems and was provided by Lipogems to the requestor in response to an unsolicited request for information. Some authors may have financial interest or receive compensation from the manufacturer. The Lipogems System is a sterile medical device intended for the closed-loop processing of lipoaspirate -issue in medical procedures involving the harvesting, concentrating and transferring of autologous adipose -issue harvested with a legally marketed lipoplasty system. The device is intended for use in the following surgical specialties when the transfer of harvested adipose -issue is desired: orthopedic surgery, arthroscopic surgery, and other specified surgical disciplines.

A Novel Treatment for a Common Cause of Shoulder Pain

Chris Cherian, MD^{1,2}, Trevor Dyson-Hudson MD^{1,3}, Gerard Malanga, MD^{1,2,4}

¹Rutgers New Jersey Medical School, Department of Physical Medicine and Rehabilitation, Newark, NJ

²Kessler Institute for Rehabilitation, West Orange, N.J.,

³Kessler Foundation, West Orange, N.J.,

⁴New Jersey Regenerative Institute, Cedar Knolls, NJ

Introduction

•Prevalence of shoulder pain is greater in patients with paraplegia compared with the rest of the population and increases regularly after an SCI^{1,2}

- 5 years – 30 to 50%
- 20 years – 70%

•Shoulder pain can negatively affect functional measures including decreased speed and efficiency of movement, increased fatigue and decreased tolerance for prolonged work and leisure activity.³

•Treatments for tendinopathy related shoulder pain

- Conservative: pharmacological agents, physical therapy, equipment modifications, education⁴
- Surgery
 - studies on rotator cuff surgery outcomes in persons with SCI are limited and conflicting
- Minimally invasive biological interventions and regenerative treatments

•Autologous Adipose Tissue

- support, cushion, repair, replacement and regeneration of soft tissue thus potentially providing mechanical, bioactive and bioavailable elements for orthopedic applications⁵

Case Presentation

•54-year-old male weight lifter with a past medical history of T10 complete spinal cord injury (SCI; American Spinal Injury Association [ASIA] grade A), surgical repair of left rotator cuff tear, presented to our outpatient clinic with complaint of right shoulder pain while weight training 3 years prior.

•His primary physician ordered an MRI which revealed a partial-thickness tear of the supraspinatus tendon along with significant degenerative changes of the AC joint and labrum.

•He was referred to an orthopedist who advised him to decrease his workout regimen and conservatively manage his pain. He received a corticosteroid injection (CSI) that provided relief at the time, with continued CSIs 2-3 times a year.

•Over the past year, his pain progressed from being intermittent to constant, non-radiating, throbbing in quality, and affecting his ability to weightlift, propel his wheelchair, sleep, and perform other activities of daily living.



Image 1. Harvested adipose tissue being injected into device for cleaning and processing



Image 2. Schematic of processing harvested adipose tissue into microfragmented adipose tissue (MAT)

Physical Examination

•**Inspection:** no signs of swelling, erythema, or deformities

•**Range of Motion:** Active range of motion for shoulder flexion/extension, internal/external rotation, and abduction/adduction were full, with pain reported past 90 degrees of abduction

•**Palpation:** no tenderness at the bicipital groove, greater tuberosity, and acromioclavicular (AC) joint

•**Strength:** Strength was rated as 5/5 throughout bilateral upper extremities with exception of pain limited right shoulder abduction and external rotation

•**Special Maneuvers:** positive Neer's and Yocum's tests, a painful arc, and positive O'Brien's test for the labrum.

Ultrasound Examination

•Partial-thickness tear of the supraspinatus tendon, degenerative changes of the labrum, and mild cortical irregularity. Minimal tendinosis of the subscapularis tendon was also appreciated.

•Dynamic testing of the supraspinatus and subscapularis did not reveal impingement.

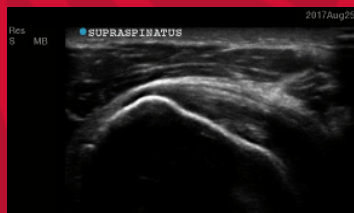

Image 3. Supraspinatus Long Axis Week 1

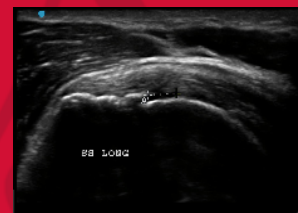

Image 5. Supraspinatus Long Axis 6 Months

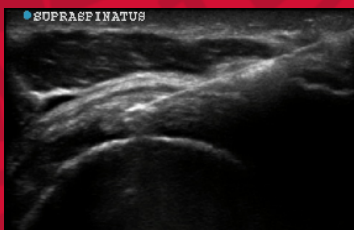

Image 4. Supraspinatus Short Axis Week 1

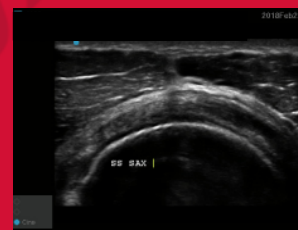

Image 6. Supraspinatus Short Axis 6 Months

Clinical Course

- The procedure was conducted a week after evaluation, with 2.5ml of MFAT injected into the supraspinatus tear, 2ml into the subacromial bursa, and 1ml into the AC joint.
- Postoperatively, he began a functional rehabilitation program at home.
- Patient was cleared to resume activities, including weightlifting after 8 weeks without restrictions
- Outcome measures included a numerical rating scale for shoulder pain (NRS; range 1-10; 0 = "no pain" and 10 = "pain as bad as you can imagine"), the Wheelchair User's Shoulder Pain Index (WUSPI; range 0 to 150, with higher values representing worse shoulder pain and function), and the Brief Pain Inventory interference items (BPI-I7).

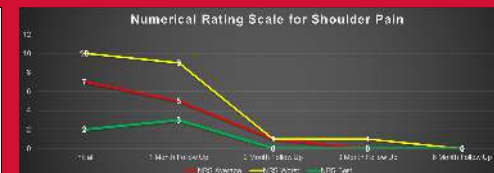


Figure A. Results of Numerical Rating Scale

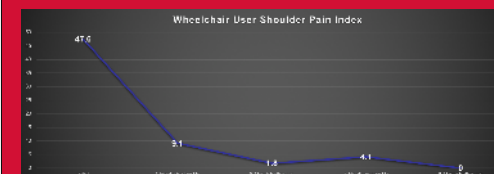


Figure B. Results of WUSPI Index



Figure C. Results of BPI-I7

Discussion

•This case illustrates a novel treatment that has shown functional improvement of shoulder pain in a weight lifting paraplegic.

•Other studies have shown similar results in other areas of the body including knees and hips^{6,7}

•Autologous Adipose Tissue contain high amounts of soluble growth factors such as bFGF, IGF-1, VEGF, TGF- β , PDGF which are known to play important regulatory roles in cellular functions

•Autologous, micro-fragmented adipose tissue (MAT) use in the able-bodied population for shoulder pain has been reported; however, not in those with SCI.

•The use of MAT for shoulder pain in the athlete has treatment potential and may allow for earlier return to play and longer relief of symptoms

References

- Gellman H, Sie L, and Waters R.L.: Late complications of the weight-bearing upper extremity in the paraplegic patient. Clin Orthop Relat Res 1988; 233 pp. 132-139
- TJ, Goh HA, Waters R.L., Adkins R.H., and Gellman H.: Upper extremity pain in the postrehabilitation spinal cord injured patient. Arch Phys Med Rehabil 1992; 73 pp. 44-48
- Curra HA, Rosen HE, Applegate EB, et al. Development of the Wheelchair User's Shoulder Pain Index (WUSPI). Paraplegia. 1995;33(5):290-293
- Medicine CSC. Preparation of upper limb following spinal cord injury: a clinical practice guideline for health-care professionals. J Spinal Cord Med 2009;28(5):434-470
- Shinohara RD, Chen H, Bittoun N, Azabulab J, Horgan K. Non-responsive knee pain with osteoarthritis and concurrent meniscal disease treated with autologous micro-fragmented adipose tissue under continuous ultrasound guidance. CellRM. 2015;3(5):1690.
- Francobaldi M, Castellani C, Minio G. Injection of autologous micro-fragmented adipose tissue for the treatment of post traumatic degenerative lesion of knee cartilage: a case report. CellRM. 2015;4(1):176
- Rusconi A, Condoello V, Madonna V, Guerrero M, & Zorzi C. (2017). Autologous and micro-fragmented adipose tissue for the treatment of diffuse degenerative knee osteoarthritis. Journal of Experimental Orthopaedics, 4(1), 33. https://doi.org/10.1186/s13047-017-0188-2