

Non-Responsive Knee Pain with Osteoarthritis and Concurrent Meniscal Disease Treated With Autologous Micro-Fragmented Adipose Tissue Under Continuous Ultrasound Guidance

R.Striano, H. Chen, N. Bilbool, K. Azatullah, J. Hilado, K. Horan

Purpose:

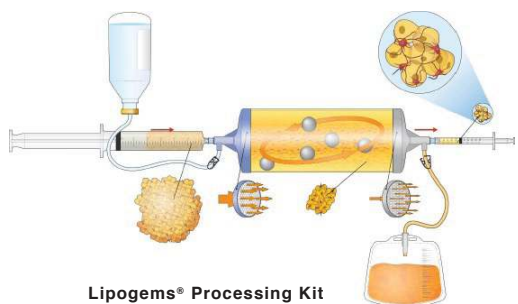
The use of autologous adipose has gained interest as a source for ortho-biologic therapies. Fat is readily accessible and simple to harvest. This adipose can be used to provide cushion and filling in of structural defects. Adipose has been shown to have an abundance of regenerative perivascular cells. In this knee pain case report we initiate our evaluation of the potential benefits of using micro-fragmented non-digested adipose tissue to obtain minimally manipulated, micronized fat tissue with an intact stromal vascular niche harboring regenerative cellular elements.

Background:

This case is the first in a 20 subject IRB to be published later that is now expanded to 100 subjects approved by IRCM. The patient is a 59 year old male with severe knee pain failing a multitude of treatments including physical therapy, NSAIDS, lifestyle modification, cortisone injection and injection with hyaluronic. Following an MRI the patient underwent arthroscopic surgery and failed to have any benefit 5 months prior to treatment with micro-fragmented adipose tissue using the (Lipogems®) technique. The MRI prior to arthroscopic surgery revealed evidence of medial compartment osteoarthritis, meniscal tear and Chondromalacia patella.

Method:

The micro-fragmented fat is derived using minimal manipulation in a closed kit system, (Lipogems®) without the addition of enzymes. The final product consists of fat droplets with preserved vascular lumina at 300-500 microns. In this treatment protocol, the Lipogems were injected with a 23-gauge needle under continuous ultrasound guidance into the joint and visualized completely filling the soft tissue defects in the meniscus defects.



No other agents were combined with the fat. Outcomes were measured immediately following the treatment, at 24 hours, 1 week, 5 weeks, 3 months, 6 months and 1 year. At 6 months, repeat MRI is performed.

Results:

We found in the first patient at 6 months and 1 year whose positive outcome may have been questionable, improvement in all measured scores. VAS pain score on a 1-10 scale with 10 being worse improved from 8/10 to 2/10 (Fig. 1), knee injury and osteoarthritis outcome score (KOOS) improved from 44.6/100 to 96.3/100 (Fig. 2). MRI 6 month's post treatment revealed the hyaline cartilage over the medial femoral condyle showed improved signal and thickness with a widened joint space. The meniscus appearance is consistent with prior surgery (Fig.3)

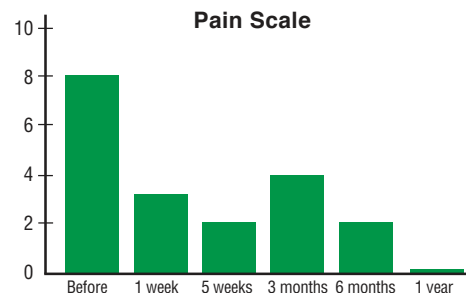


Figure 1: This graph displays the Visual Analog Scale (VAS), which measures the pain intensity of the joint that is being treated. It runs on a scale from 0 to 10, with 0 being no pain and 10 being the worst pain.

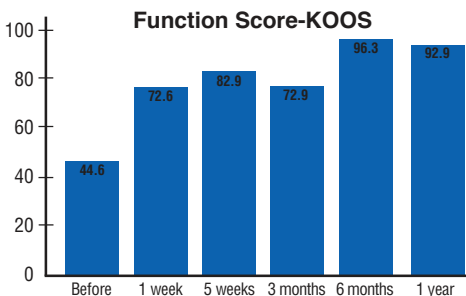


Figure 2: This graph displays the Knee Injury and Osteoarthritis Outcome Score (KOOS), which measures a score based on the patient's conception of their knee and related problems. A perfect score for the KOOS is a 100.

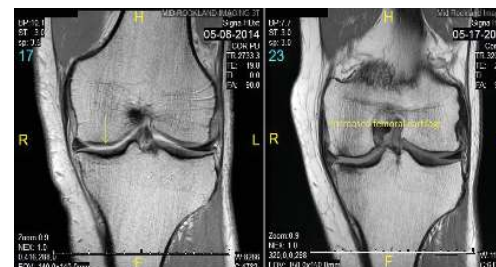

Figure 3: Left) MRI prior to treatment revealing medial compartment degeneration (arrow). Right) MRI 6 months after treatment with widening of the joint space and improved signal and thickness of the cartilaginous tissue (yellow arrow). MRI prior to treatment reveals a thinning articular cartilage measured by Radiologist to be 0.75mm. MRI taken 6 months post treatment reveals an improved thickened articular cartilage measured by Radiologist at 1.5mm of cartilage. Meniscus changes are not comparable in the 6 month post treatment MRI as the patient underwent arthroscopic surgery of the meniscus following the original pre-treatment MRI.

Discussion:

Due to arthroscopic surgery following the MRI prior to the treatment with micro-fragmented adipose tissue the change in the meniscus 6 months after treatment is not comparable as no immediate pre-treatment image was available. While ultrasound imaging of the fibro-cartilage meniscus is not considered diagnostic of the meniscus, the present meniscal tissue did appear to have enhanced internal echotexture, appeared more hyperechoic and homogenous. We believe the precision of continuous ultrasound imaging to diagnostically develop targets of interests for treatment and its use in guidance of the needle in real time enabling the visualization of coverage of each of the soft tissue defects contribute to the positive outcomes achieved. While further study is underway, these results in a case with multiple abnormalities treated with autologous micro-fragmented adipose tissue appear promising as a viable treatment for non-responsive knee pain.