



Research Article

Refractory Shoulder Pain with Osteoarthritis, and Rotator Cuff Tear, Treated With Micro-Fragmented Adipose Tissue

Richard D Striano^{1*}, Gerard A Malanga², Norma Bilbool³, Khatira Azatullah⁴

¹Optimum Joint, Integrated Joint and Spine, Suffern, NY, USA

²New Jersey Regenerative Institute, Cedar Knolls, NJ, USA

³Optimum Joint, Integrated Joint and Spine, Suffern, NY, USA

⁴Optimum Joint, Integrated Joint and Spine, Suffern, NY, USA

Abstract

Background: Chronic shoulder pain and rotator cuff abnormalities affect a large portion of the population and result in substantial impairments and loss of useful functions, thus affecting patient quality of life. One of the most common causes of shoulder pain in the adult population is osteoarthritis. It is the third most prevalent musculoskeletal disorder after low back and neck pain. If current standard non-operative methods fail, there are few viable options available other than shoulder replacement surgery. Recently biological treatments using adult stem cell treatments, Mesenchymal Stem Cells (MSC's) have been shown to have potential benefits in orthopedic applications. One such source of regenerative cellular tissue is adipose, which is known to be a robust source of stem cells. Adipose tissue is readily accessible, easily harvested and few complications have been reported. This study embarks on reporting the safety, efficacy and long term benefits from ultrasound guided injection of an autologous, minimally manipulated, micro-fragmented adipose tissue.

Materials and Methods: An explanation of the treatment was provided and informed consent obtained. The micro-fragmented adipose tissue was obtained with minimal manipulation using Lipogems® (Lipogems USA, Atlanta Ga.) a closed system using normal saline cleansing; mild mechanical separation of waste products and reduction filters. The system provides a lipoaspirate without the addition of enzymes or any other additives. The final product consists of adipose tissue clusters with preserved vascular stromal niche of approximately 500 microns. The injections were delivered into the joint and each soft tissue abnormality under direct ultrasound guidance as was found to be clinically relevant. Numeric pain scores and The American Shoulder and Elbow Surgeons Score (ASES) were collected immediately following treatment, and at weeks 1 and 5, months 3, 6 and 12.

Results: Significant improvement was noted through all time points to one year. Outcomes assessed immediately following treatment, at weeks 1 and 5, months 3, 6 and 12 by Numerical Pain Scale (NPS) and The American Shoulder and Elbow Surgeons Score (ASES). NPS ($p < 0.00008$), ASES ($p < 0.00017$). The average improvement of NPS was from 7.5 to 3.6 at one year. The average ASES from 33.7 to 69.2 at one year (0-100 scale 100 perfect function). No post procedural complications or serious adverse events were reported.

Conclusions: While the limitations of this study are a low number of subjects and not a randomized controlled trial, it is noteworthy that most published studies are shorter term follow up 3-6 months. The results from this study demonstrate significant improvements in pain, function and quality of life as represented by positive outcomes in all measured scores through twelve months.

Keywords: Lipogems®; Adipose Tissue; Osteoarthritis; Rotator Cuff; Tendinopathy; Shoulder Pain; Mesenchymal Stem Cell

Introduction

Treatment of shoulder pain from osteoarthritis, rotator cuff abnormalities presents a clinical challenge for effective non-surgical methods when current standards of care fail. Ultrasound imaging as a diagnostic tool has been shown to correlate with MRI and ultrasound shown enhanced accuracy when guiding injections [1,2]. In a recent study ultrasound guided injections of the glenohumeral joint

Received February 07, 2018; Accepted February 15, 2018; Published February 22, 2018

*Corresponding author: Richard D Striano, Optimum Joint, Integrated Joint and Spine, Suffern, NY, USA, Tel: (845) 425-3918; Email: rstriano@aol.com

Citation: Striano RD, Malanga GA, Bilbool N, Azatullah K (2018) Refractory Shoulder Pain with Osteoarthritis, and Rotator Cuff Tear, Treated With Micro-Fragmented Adipose Tissue. Orthop Spine Sports Med 2: JOSM 014.

demonstrated greater improvement in function over blind injections [3]. When injecting tendons accurate placement may play an even more important role. The dual role of ultrasound may be particularly important when delivering cellular products into specific structures and soft tissue defects.

Regenerative cells in orthopedic applications are typically harvested from bone marrow aspirate or adipose tissue. Adipose tissue has gained interest in this regard, and the ease of accessibility by minimally invasive methods, and simple preparation methods for injection have added to the interest. A point debated is whether bone marrow MSC's may be suboptimal for some clinical applications due to the decline in both their proliferation and differentiation with increasing senescence [4,5]. While the debate for best sourcing will continue, current thinking of all sources attributes the likely therapeutic effectiveness of cellular treatments not to "cell stemness" but to paracrine activity. More specifically, in addition to many trophic activities, the MSC derived extracellular vesicles; exosomes play important roles as mediators [6]. It has been reported in animal studies that MSC secretome mediates regenerative processes in tissue undergoing degeneration, concluding the proteomic analysis revealed the presence of important proteins with muscle regeneration, namely pigment epithelium-derived factor and filastatin [7]. Rotator cuff tears in the adult are usually chronic lesions with pronounced degenerative changes, where advancing fatty degeneration and atrophy can lead to irreparable damage. This study sheds light on the potential for the prevention of muscle changes associated with chronic rotator cuff tear.

In another recent study, aimed at deciphering the secretomes from adipose derived stromal cells more than 600 proteins were detected in conditioned media of adipose derived stem cells. Of those, 100 secreted proteins included key molecules involved in tissue regeneration [8]. A recent study has elucidated the role of TGF- β has shown adipocytes can dedifferentiate into precursor cells and that a proliferative cell population could be useful in cellular therapy [9]. Along with anti-inflammatory effects, ASC secrete various factors that may modulate metabolism of extracellular matrix in Osteoarthritic (OA) cartilage, suggesting that the presence of ASC could be advantageous for OA cartilage due to the recovery of homeostasis between Matrix Metalloproteinase's (MMPs) and their Tissue Inhibitors Of Metalloproteinase's [TIMPs] [10]. Another recent study of human adipose derived stem cells highlighted that the adipose cellular exhibit enhanced proliferative capacity and retain multi-potency longer than donor-matched marrow MSC during expansion [11]. As more emphasis is placed on the immunomodulatory component amongst others associated with activities of adipose derived cellular therapy, it has been shown that ASCs exert their immunoregulatory effects mainly through the secretion of paracrine factors. Indeed, oxidative stress induces ASCs to secrete TGF- β , which promotes premature T helper (Th) differentiation toward regulatory T cells. Consequently, the Th1 inflammatory response is down regulated, promoting

immune tolerance. ASCs also secrete galectin-1 and -3, which are essential in T-cell suppression, and metabolize l-arginine, limiting its bioavailability, thereby reducing T-cell proliferation and function [12].

In an animal study of the supraspinatus tendinopathy treated with adipose derived stem cells and platelet rich plasma in 55 canine patients, all showed significant improvement in function along with improved imaging characteristics and tendon size on diagnostic ultrasound imaging follow up [13]. Availability of an autologous, minimally manipulated, micro-fragmented adipose tissue is of potentially great clinical significance. A new non-enzymatic method to obtain an adipose tissue highly enriched in pericyte like elements has been developed. It has also been reported that the digestion of adipose tissue to obtain a stromal vascular fraction loses many important bioactive elements in the processing to a purely cellular product [14].

Case description

Here we present a study of 18 subjects in a 20 subject study where 2 subjects were lost to one year follow up, IRB approved by IRCM (LGS-104) one year following treatment. The aim of the study is highlighting the safety, efficacy and long term benefits of a non-enzymatic adipose tissue treatment for shoulder pain that is refractory to a variety of conservative treatments. Each subject has chronic progressive shoulder pain and loss of useful function that include restricted range of motion, pain elevating the arm, inability to reach behind the neck or back, difficulty dressing, inability to raise the arm above 90 degrees, pain when sleeping on the affected side, weakness and loss of quality of life. Each subject has pain exceeding one year. Inclusion criteria consisted of pain exceeding one year, no cortisone or other injections within 60 days, evidence of pathology on MRI and one subject diagnostic ultrasound alone, failing prior treatment to include at least three of the following: Physical therapy, cortisone injections, home exercise, platelet rich plasma, and viscosupplementation. Abnormalities were demonstrated by MRI and in one subject by musculoskeletal ultrasound alone. **Table 1** lists the individual abnormalities. Exclusion criteria included cortisone injection within 60 days, oral prednisone, rheumatoid arthritis, injectious disease, cancer or other systemmic comorbidity researches felt was exclusionary.

Subject Demographics

Table 1 summarizes subject demographics. 20 subjects met criteria. Mean age was 65.9 years old with Body Mass Index (BMI) of 32.2 kg/m². Abnormalities on MRI of the shoulder and rotator cuff are listed below. One subject confirmed by ultrasound imaging alone.

Materials and Methods

Pre-treatment point of care targets of interest were developed by musculoskeletal ultrasound imaging and collated with historical MRI imaging, to map out the treatment plan and determine the approximate final volume

Subject Demographics and Pathology (18 subjects)	
Average age	65.9
Average BMI	32.2 kg/m ²
Laterality	
Right	13 (72.2%)
Left	7 (35%)
Glenohumeral osteoarthritis severity	
None	1 (5%)
Mild	2 (10%)
Moderate	5 (25%)
Severe	12 (60%)
Acromio-clavicular osteoarthritis	11 (55%)
Rotator cuff pathology	
Bicep Tendon	
Tendinosis	1 (5%)
Partial Tear	4 (20%)
Subscapularis Tendon	
Tendinosis	5 (25%)
Partial Tear	1 (5%)
Supraspinatus Tendon	
Tendinosis	9 (45%)
Partial Tear	9 (45%)
Full Thickness Tear	6 (30%)
Infraspinatus Tendon	
Tendinosis	7 (35%)
Partial Tear	1 (5%)
Full Thickness Tear	1 (6%)
Labral Tear	7 (35%)
Fatty Atrophy	6 (30%)

Table 1: Patient demographic summary.

of adipose tissue required to treat the intended clinically relevant abnormalities in the shoulder. An approximate volume of lipoaspirate to finished adipose tissue is 4:1. Clinical outcomes were measured immediately following the treatment, at weeks 1 and 5, months 3, 6 and 12. The subjects will be followed up until 2 years. The subjects were placed supine, and the skin overlying the abdomen was prepped with a Betadine solution and draped in the usual sterile fashion. A tumescent fluid was prepared by diluting a 50ml of a 2% lidocaine solution with 1 ml of a 1mg per ml. epinephrine solution in 500ml normal saline for use infiltrating the fat layer of the abdomen. After a local anesthetic was injected, two small incisions were made with the bevel of an 18 gauge needle below the umbilicus and laterally to the midline of the abdomen to avoid penetrating the linea Alba. The anesthetic tumescent fluid was injected through the orifices and fanned in various directions using a 17 gauge blunt cannula in a spokes on a wheel fashion creating channels in the subcutaneous fat below Scarpa's fascia. Following infiltration with anesthetic tumescent the cannula was used to retrace the spokes on a wheel pattern made during the infiltration to evenly distribute tumescent and pre-tunnel the subcutaneous fat for harvest. Fifteen minutes was allowed for the tumescent to sit prior to harvesting to reduce bleeding. The fat was then harvested from both sides of the abdomen using a 13 gauge blunt cannula attached to a VacLok 30 ml. syringe. The harvested fat was then introduced into the Lipogems® processing kit. After processing the finished adipose tissue was loaded into 1cc aliquots for injection.

The Lipogems® processing kit consists of a disposable kit for the aspiration, processing and reinjection of autologous, minimally manipulated and Microfragmented adipose tissue in both human and veterinary medicine. At its core is a disposable and closed device, filled with saline solution that progressively reduces the size of the clusters of adipose tissue by means of mild mechanical forces, and special filters while eliminating pro-inflammatory oil and blood residues. The technique is gentle, and intra-operatively provides autologous, minimally manipulated and micro-fragmented fat in a short time (60-90 minutes), without expansion and/or enzymatic treatment. The vascular-stromal niches of the prepared adipose survive in the site of the injection and improve tissue health. During the processing the subjects remained supine, and a bolster was placed under the knees for comfort.

Interventional ultrasound guidance was administered using a GE Logiq P6, Analogics BK3000 or Analogics BK5000 ultrasound system each fitted with a linear 4-15/18Mhz probe used for rotator cuff and tendons and acromioclavicular joint and a curvilinear 2-6MHz probe used for the glenohumeral joint and labrum.

For the glenohumeral joint, the subjects were placed side-lying with the symptomatic shoulder skyward. The injection site was prepped in the usual sterile fashion. Ultrasound imaging was made using a curvilinear 2-6MHz probe. Via a posterior approach an in plane descent to the glenohumeral joint was made. 1% Lidocaine as local anesthetic in route to the glenohumeral joint but not in close proximity to the joint was used to improve patient comfort. Using a 22 gauge 2.75 inch needle tip and placement within the glenohumeral joint was confirmed, and 4cc of adipose in 1cc aliquots was injected into the joint, visualizing the injectate spread infiltrating the joint confirming accurate placement.

Following the glenohumeral joint injection, as clinically relevant, the needle was then partially withdrawn and 2cc of adipose in 1cc aliquots was injected bathing the posterior surface of the glenoid labrum visualizing the injectate spread covering the echogenic labral contour. As clinically relevant the infraspinatus was injected from the same posterior approach with an in plane approach 1-2cc was injected.

For the rotator cuff and bicep tendons, subjects were placed supine with the symptomatic arm in a modified neutral position for the supraspinatus, and the elbow bent at 90 degrees and slight internal rotation for the bicep tendon, and arm externally rotated for the subscapularis tendon. 1-2cc was injected into each tendon or tendon tear as clinically relevant. Injectate flow filling the soft tissue defect or into the heterogeneous tendinotic tissue was visually confirmed for accurate placement.

For the acromioclavicular joint, subjects were placed supine with the arm in a neutral side position. 1cc was injected as clinically relevant. Injectate flow filling the joint was visually confirmed for accurate placement.

Injection sites were cleaned and adhesive bandages applied. The subjects tolerated the treatment well and no peri-procedural complications or adverse events were reported.

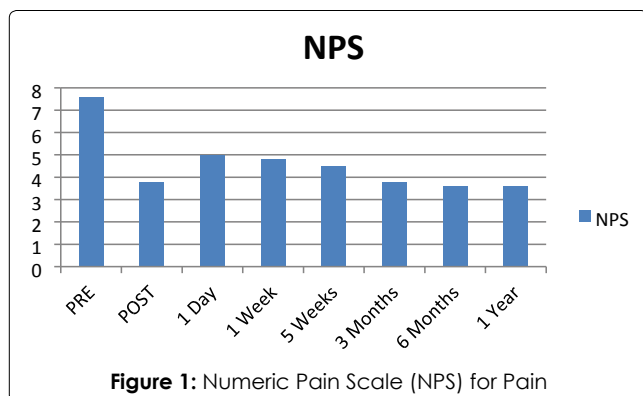


Figure 1: Numeric Pain Scale (NPS) for Pain

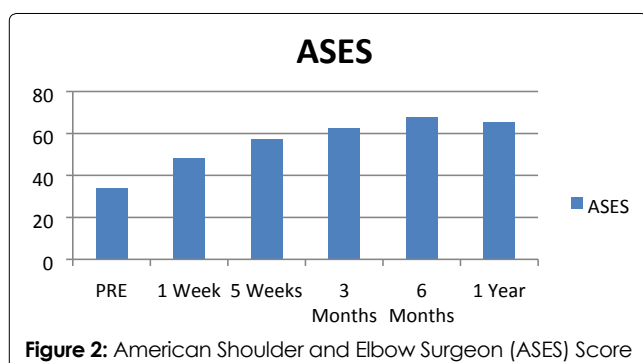


Figure 2: American Shoulder and Elbow Surgeon (ASES) Score

Results

Pre-treatment scores were taken and post-treatment outcomes were determined using NPS, Numeric Pain Scale and the ASES American Shoulder and Elbow Surgeons Score, on a 1-100 scale with 100 being perfect function. One year following the treatment, we initiated the report with 20 subjects completing the one year follow up. We found significant improvement through twelve months in all measured scores. NPS pain score on a 1-10 scale, with 10 being worse, had a pre-treatment average of 7.94 that improved to 3.7 at month 12. ASES on a 1-100 scale with 100 being a perfect score improved from a 33 pre-treatment to a 66 at month twelve (Figures 1 and 2).

Baseline NPS vs 12 months ($p < 0.0001$). Most significant improvement occurred during the first 24 hours of the treatment, with sustained benefit through 12 months follow up.

There was a significant improvement in ASES scores between baseline and all time points at week 1-5, 3 months, 6 months, and 12 months ($p = 0.0033$, $p < 0.0001$, $p < 0.0001$, $p < 0.00017$, respectively). There appears to be near-linear improvement in the score during the first 3 months with sustained improvement through 12 months follow up

Discussion

The results from this study demonstrate significant improvements in pain, function disability and quality of life as represented by positive outcomes in all measured scores through twelve months with no adverse events reported. The authors believe the use of precision ultrasound guidance in addition to the treatment of multiple clinically relevant structure contributes to the long-term benefits observed. It is noteworthy while not the often preferred randomized control trial, a majority of recent studies on the rotator cuff with platelet rich plasma or bone marrow concentrate report

shorter term outcomes, 3-6 months and the sustained twelve month outcomes in this study are significant. In this vein the author think additional lines of research into the benefits of intact adipose tissue that is not enzymatically processed in treating the shoulder joint and rotator cuff should be explored. The results from this study demonstrate significant improvements in pain, function disability and quality of life as represented by positive outcomes in all measured scores through twelve months with no adverse events reported.

Conclusion

The limitations of this study include a low number of subjects and that the study is not a randomized controlled trial. The results are very encouraging. The autologous, minimally manipulated, micro-fragmented adipose tissue administered under continuous ultrasound guidance, appears to be safe, effective and producing long term results in the treatment of shoulder pain having multi-factorial origins.

Further study in musculoskeletal conditions is warranted.

References

- Nabetani Y, Watanabe T, Terabayashi N, et al. (2014) Diagnostic ability of ultrasonography for the rotator cuff tear: comparison with ultrasonography and MRI findings. *Rinsho Byori* 62: 31-37.
- Aly, Abdel-Rahman, Rajasekaran S, Ashworth N (2014) Ultrasound-guided shoulder girdle injections are more accurate and more effective than landmark-guided injections: a systematic review and meta-analysis. *British journal of sports medicine* (2014): bjsports-2014.
- Raeissadat SA, Rayegani SM, Langroudi TF, Khoiniha M (2016) Comparing the accuracy and efficacy of ultrasound-guided versus blind injections of steroid in the glenohumeral joint in patients with shoulder adhesive capsulitis. *Clin Rheumatol*.
- Frese L, Dijkman PE, Hoerstrup SP (2016) Adipose Tissue-Derived Stem Cells in Regenerative Medicine. *Transfus Med Hemother* 43: 268-274.
- Koobatian MT, Liang MS, Swartz DD, Andreadis ST (2015) Differential effects of culture senescence and mechanical stimulation on the proliferation and leiomyogenic differentiation of MSC from different sources: implications for engineering vascular grafts. *Tissue Eng Part A* 21: 1364-1375.
- Lo sicco C, Reverberi D, Balbi C, et al. (2017) Mesenchymal Stem Cell-Derived Extracellular Vesicles as Mediators of Anti-Inflammatory Effects: Endorsement of Macrophage Polarization. *Stem Cells Transl Med* 6:1018-1028.
- Sevivas N, Teixeira FG, Portugal R, et al. (2016) Mesenchymal Stem Cell Secretome: A Potential Tool for the Prevention of Muscle Degenerative Changes Associated With Chronic Rotator Cuff Tears. *Am J Sports Med*. 2016.
- Kalinina N, Kharlampieva D, Loguinova M, et al. (2015) Characterization of secretomes provides evidence for adipose-derived mesenchymal stromal cells subtypes. *Stem Cell Res Ther* 6: 221.
- Côté JA, Lessard J, Pelletier M, et al. (2017) Role of the TGF- β pathway in dedifferentiation of human mature adipocytes. *FEBS Open Bio* 7: 1092-1101.
- Denkovskij J, Bagdonas E, Kusleviciute I, et al. (2017) Paracrine Potential of the Human Adipose Tissue-Derived Stem Cells to Modulate Balance between Matrix Metalloproteinases and Their Inhibitors in the Osteoarthritic Cartilage In Vitro. *Stem Cells Int* 2017: 9542702.

11. Burrow KL, Hoyland JA, Richardson SM (2017) Human Adipose-Derived Stem Cells Exhibit Enhanced Proliferative Capacity and Retain Multipotency Longer than Donor-Matched Bone Marrow Mesenchymal Stem Cells during Expansion In Vitro. *Stem Cells Int* 2017: 2541275.
12. Bertozzi N, Simonacci F, Grieco MP, Grignaffini E, Raposio E (2017) The biological and clinical basis for the use of adipose-derived stem cells in the field of wound healing. *Ann Med Surg (Lond)*. 20: 41-48.
13. Canapp SO, Canapp DA, Ibrahim V, Carr BJ, Cox C, et al. (2016) The Use of Adipose-Derived Progenitor Cells and Platelet-Rich Plasma Combination for the Treatment of Supraspinatus Tendinopathy in 55 Dogs: A Retrospective Study. *Front Vet Sci* 3: 61.
14. Bianchi F, Maioli M, Leonardi E, et al. (2013) A new nonenzymatic method and device to obtain a fat tissue derivative highly enriched in pericyte-like elements by mild mechanical forces from human lipoaspirates. *Cell Transplant* 22: 2063-2077.