

# Non-Responsive Shoulder Pain with Osteoarthritis, Rotator Cuff Tear and Labral Tear Treated With Autologous Micro-Fragmented Adipose Tissue Under Continuous Ultrasound Guidance

R.Striano, N. Bilbool, K. Azatullah, J. Hilado

## Background:

Background: Chronic shoulder pain and rotator cuff abnormalities affect a large portion of the population and result in substantial impairments and loss of useful functions, thus affecting patient quality of life. These often include pain, loss of range of motion, stiffness, pain increased with activity and gradual worsening over time.

## Objective:

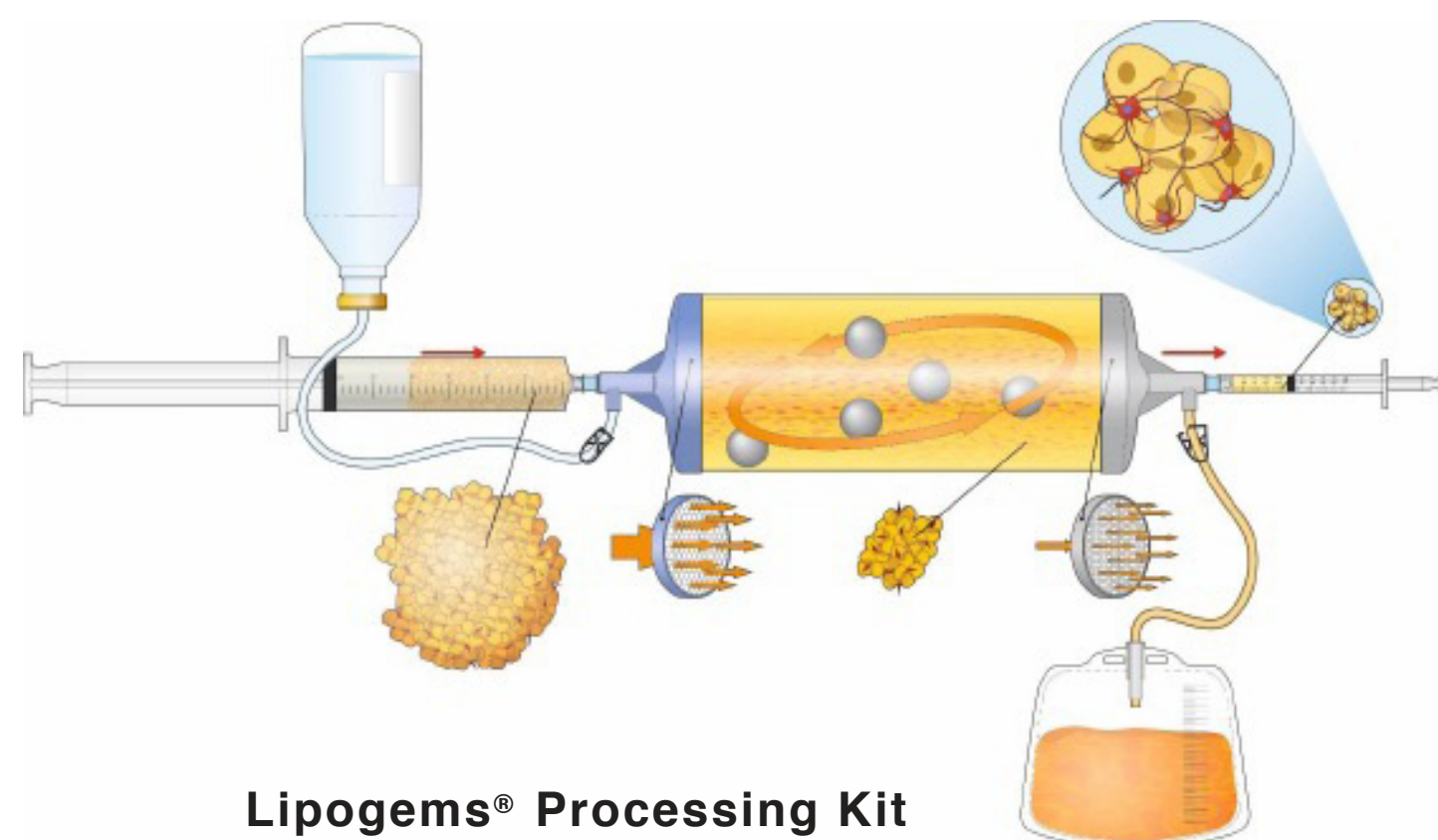
We initiated our evaluations on the potential benefits of using micro-fragmented non-digested adipose tissue to obtain minimally manipulated and micronized fat tissue with intact stromal vascular niches harboring regenerative cellular elements. This is a case of non-responsive shoulder pain with multiple abnormalities involving the joint, rotator cuff and fibrocartilage labrum. All of these were clinically relevant.

## Case description:

The patient is a 44-year-old female with chronic progressive shoulder pain and loss of useful function. She had restricted range of motion, inability to raise the arm, pain when sleeping on the affected side, weakness and disability from work. Treatment with NSAIDs, physical therapy, steroid injection, and Hyalgan® viscosupplementation afforded an unsatisfactory benefit. MRI revealed glenohumeral osteoarthritis, partial tear of the supraspinatus, tearing of the glenoid labrum and a para-labral cyst. Being a police officer, the patient refused surgery.

## Material and Methods:

The micro-fragmented adipose tissue was obtained with minimal manipulation using Lipogems®, a closed system using mild mechanical forces and reduction filters. The system processes lipoaspirate without the addition of enzymes or any other additives. The final product consists of adipose tissue clusters with pre-



served vascular stromal niche of approximately 500 microns. In this treatment protocol, the micro-fragmented fat was injected with a 22-gauge needle under continuous ultrasound guidance into the glenohumeral joint, then bathing the labrum as the needle is visualized withdrawing from the glenohumeral joint. A second ultrasound guided injection was administered intrasubstance into the supraspinatus tendon visualizing the filling of the heterogeneous, hypoechoic soft tissue defects. No other biological or pharmacological agents were used. Clinical outcomes were measured immediately following the treatment, at 24 hours, 1 week, 5 weeks, 3 and 6 months. The patient will be followed up until 2 years, and at 6 – 9 months MRI will be performed. Here we report the results at 6 months.

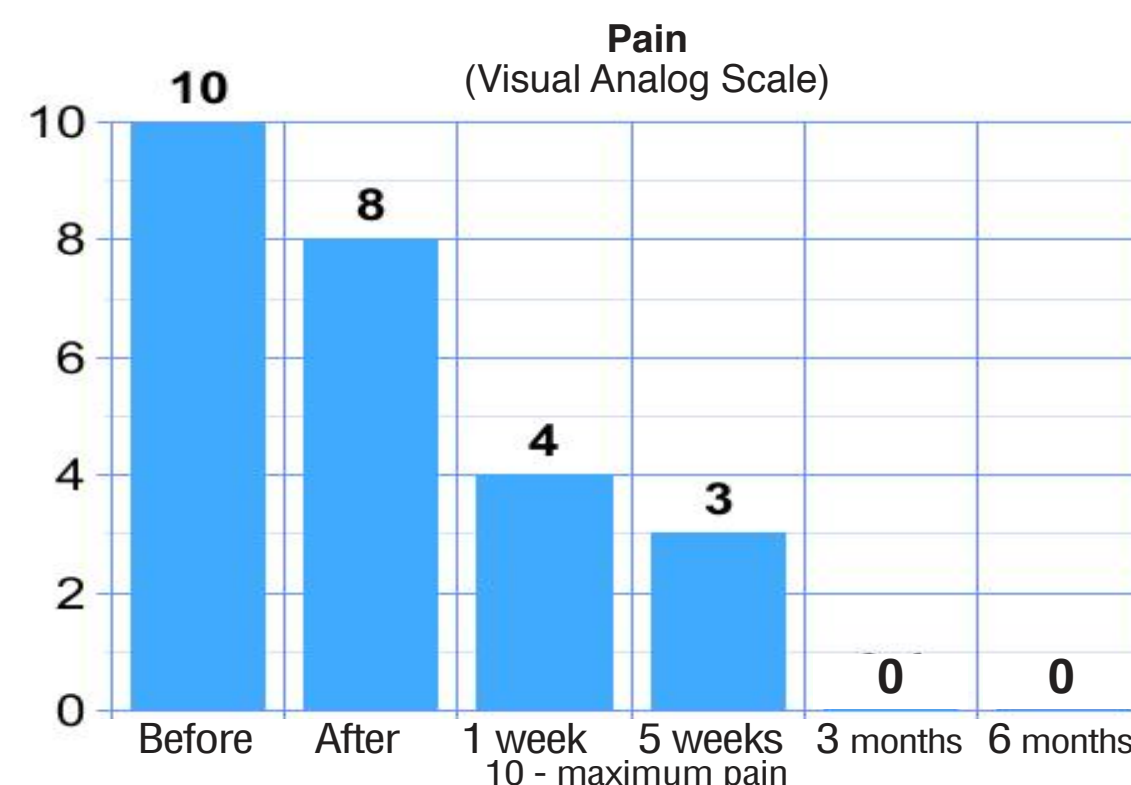


Fig 1: Pain was measured by the VAS Visual Analogue Scale range from 1 – 10 with 10 being worst pain.

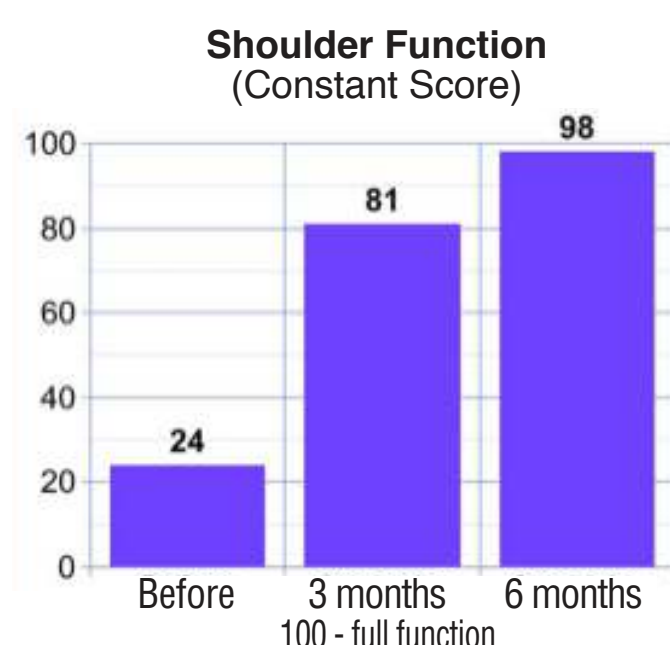

Fig 2: CONSTANT Shoulder Function Score range from 0 – 100 with 100 being perfect function.

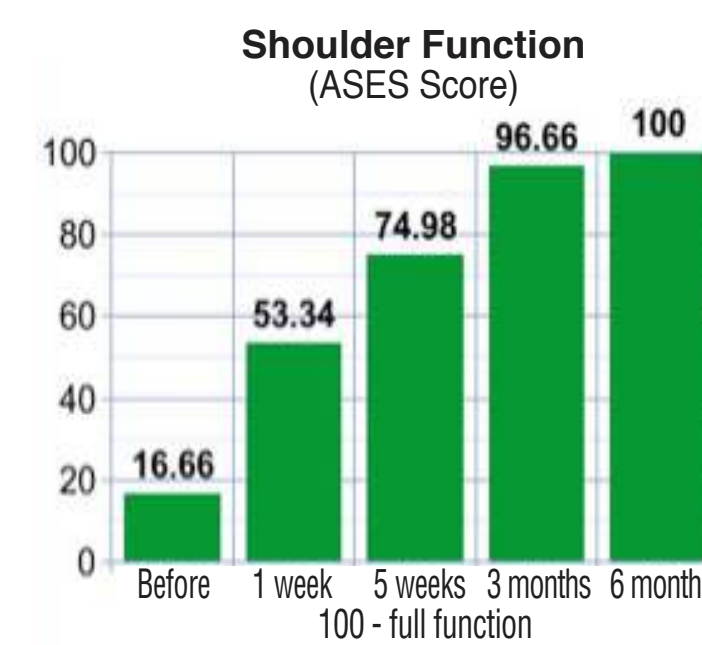

Fig 3: Function score ASES with a range from 0 – 100 with 100 being perfect score.

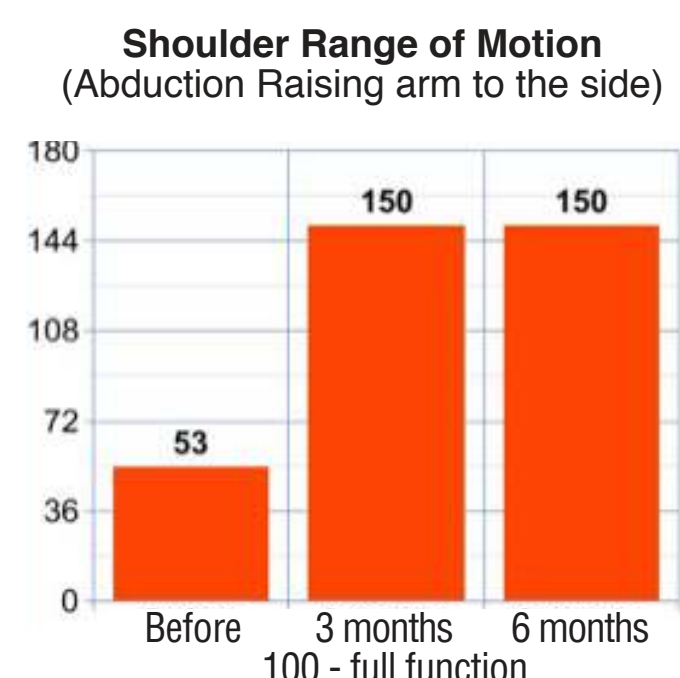


Fig 4: Range of motion measured in abduction by instrumentation by the same therapist at each end point in degrees from 0 – 180 with 180 being full range of motion.

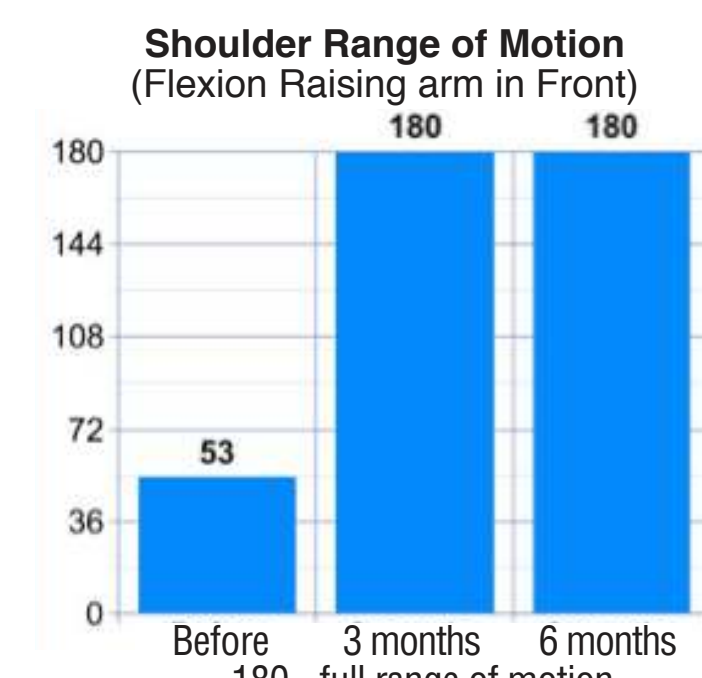

Fig 5: Range of motion measured in forward flexion by instrumentation by the same therapist at each end point in degrees from 0 – 180 with 180 being full range of motion.

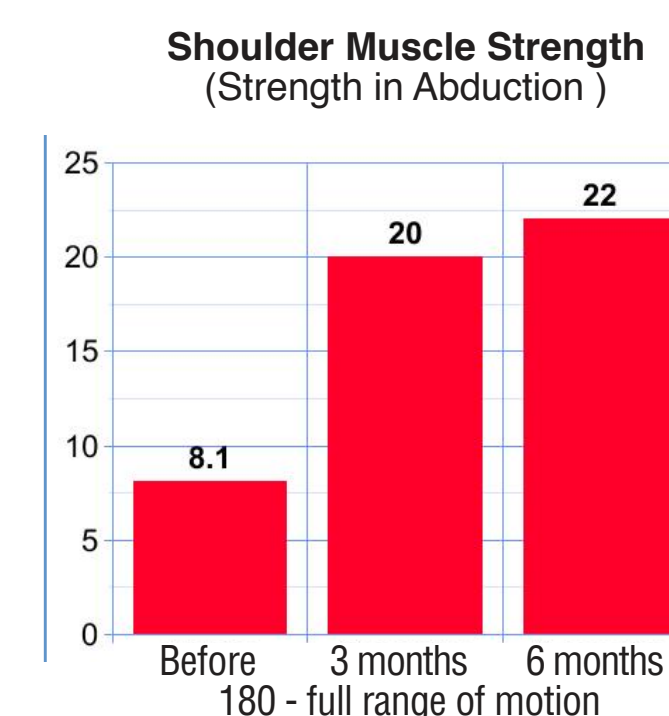


Fig 6: Muscle strength measured in forward flexion by instrumentation by the same therapist at each end point in lbs/in2

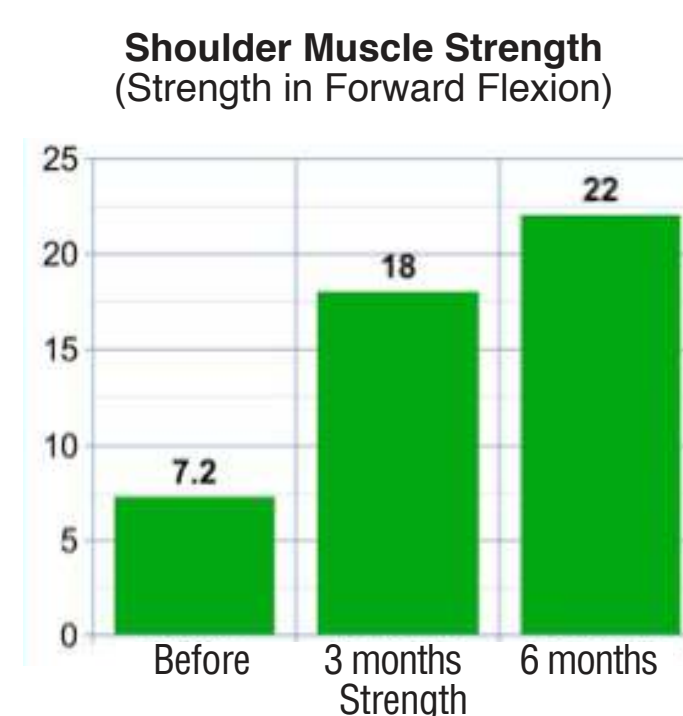

Fig 7: Muscle strength measured in abduction by instrumentation by the same therapist at each end point in lbs/in2

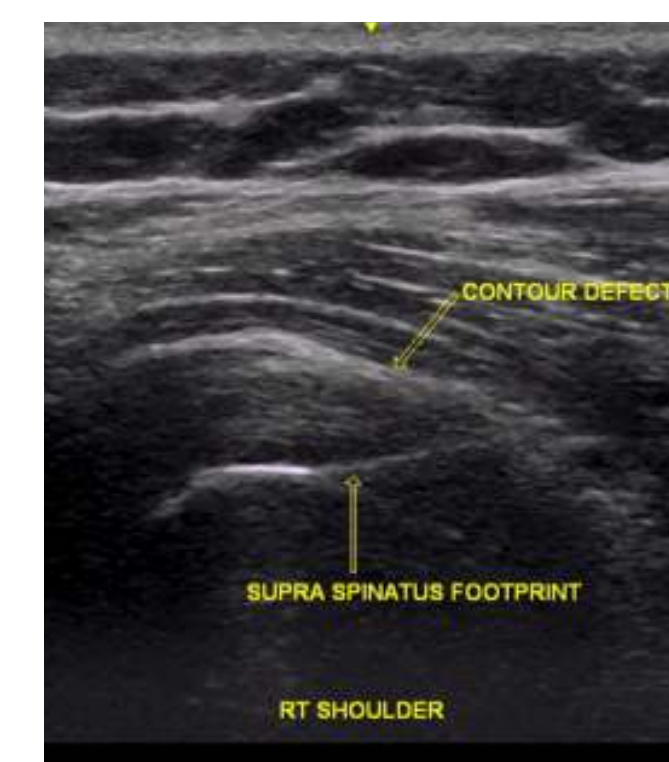


Fig 8: Pre-treatment ultrasound image of the supraspinatus tendon reveals a hypoechoic, heterogeneous echotexture with thinning of the supraspinatus tendon showing a contour defect (arrow), consistent with a tear.

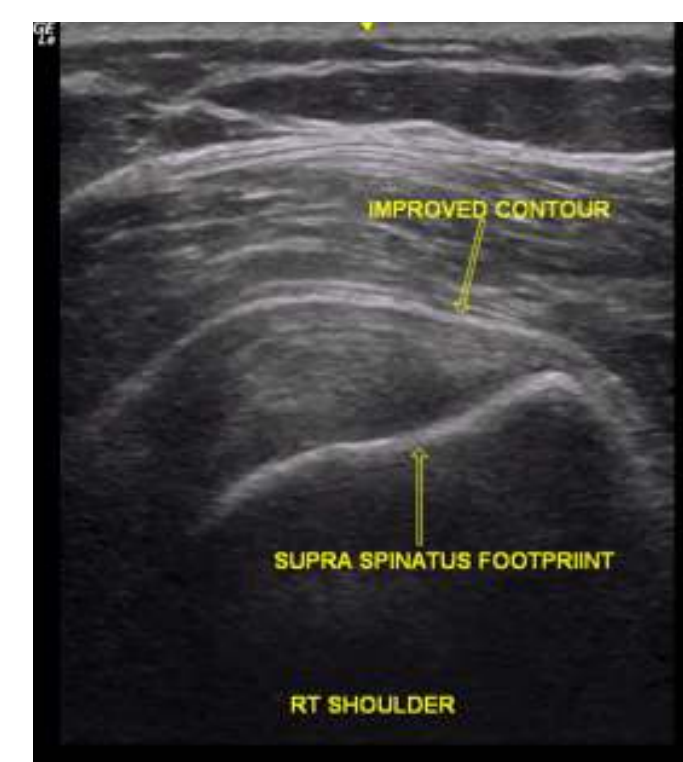


Fig 9: Six month follow up ultrasound image reveals a more robust, hyperechoic, homogeneous supraspinatus tendon echotexture with improvement of the contour defect (arrow)..

## Results:

Six months after Lipogems® injection, all the measured scores improved (Fig 1-9). In details, VAS pain score improved from 10 to 0 (0-10 scale), ASES from 16.66 to 96.66 (100 being perfect), and Constant Shoulder Score from 24 to 81 (100 being perfect). Range of motion, measured with a goniometer by the same therapist, improved from abduction 53 degrees and forward flexion 53 degrees to 150 degrees and 180 degrees respectively. Muscle strength, measured with instrumentation by the same therapist, improved forward flexion of 8.1lb/in2 and abduction of 7.2lb/in2 to 20lb/in2 and 18lb/in2 respectively. Ultrasound imaging revealed improved homogeneity, tendon contours and internal echotexture of the supraspinatus tendon.

## Conclusion:

Although this is a single case report, the injection of autologous, micro-fragmented, minimally manipulated adipose tissue obtained with the new device Lipogems® appears a promising potential viable treatment in a case of non-responsive shoulder pain from multiple joint and soft tissue abnormalities.