

Non-Responsive Knee Pain with Osteoarthritis and Concurrent Meniscal Disease Treated With Autologous Micro-Fragmented Adipose Tissue Under Continuous Ultrasound Guidance

R.D. Striano, H. Chen, N. Bilbool, K. Azatullah, J. Hilado, K. Horan

Regenerative Medicine, Optimum Joint, New York, USA

Corresponding Author: Richard David Striano, D.C. RMSK; e-mail: rstriano@aol.com

Keywords: Lipogems®, Knee pain, Micro-fragmented adipose tissue, MSC properties, Osteoarthritis.

ABSTRACT

Background: Adipose tissue has gained increased interest in the medical and scientific community over the last few years as a source for ortho-biologic therapies. It is readily accessible and simple to harvest. Adipose can be used to provide cushioning and filling of structural defects and has been shown to have an abundance of bioactive elements and regenerative perivascular cells.

Objectives: To evaluate the potential benefits of injecting a severely arthritic knee with concurrent meniscal disease with micro-fragmented non-digested adipose tissue using a novel technique by obtaining minimally manipulated and micronized fat tissue with intact stromal vascular niches harboring regenerative cellular elements. The case is non-responsive knee pain with osteoarthritis and concurrent meniscal disease.

Case Description: This case is the first of a 100-subject IRB study approved by IRCM. The patient is a 59-year-old male with severe knee pain who has failed a multitude of treatments, including arthroscopic meniscal surgery. The MRI prior to surgery revealed evidence of osteoarthritis, medial meniscal tear, and chondromalacia patella. The patient was followed for 6 months, and will continue to be followed for two years.

Materials and Methods: Micro-fragmented fat was obtained by using a minimal manipulation technique in a closed system (Lipogems®), without the addition of enzymes or any other additives. The final product consisted of micronized fat tissue yielding fat clusters with preserved vascular stroma of about 500 microns with intact stromal vascular niches and harboring regener-

ative cellular elements. In this treatment protocol, the micronized fat was injected with a 22-gauge needle under continuous ultrasound guidance into the joint and filling the hypoechoic defects in the medial meniscus. No other biological or pharmacological agents were used in combination with the micronized fat.

Outcomes were measured immediately following the treatment, 24 hours, 1 week, 5 weeks, 3 months, 6 months and 1 year after the injections. At 6 months, a repeat MRI of the joint was performed.

Results: One year after the treatment, we found improvement in all measured scores. VAS pain score on a 1-10 scale, with 10 being worse, improved from 8 to 0; the KOOS (Knee Injury and Osteoarthritis Score) outcome, with a score of 100 being perfect, improved from 45 to 92.9. MRIs taken at 6 months post-treatment, revealed improved signal and thickness of the cartilaginous tissue over the medial femoral condyle, with a widened joint space. Radiologist initial measure of articular cartilage reported as 0.75 mm and at 6 months reported as 1.5 mm.

Conclusion: The injection of autologous micro-fragmented adipose tissue obtained with the new technique, Lipogems® in the case of non-responsive knee pain appears to be a promising and viable treatment. Due to the arthroscopic surgery taking place following the original MRI and prior to the treatment with micronized fat, the change in the meniscus after 6 months is not comparable. Further studies are underway.

INTRODUCTION

Osteoarthritis is a common cause of musculoskeletal pain and disability in the knee joint. Symptoms of osteoarthritis affect the patients quality of life and

often includes joint pain with activity, reduced mobility, incomplete weight bearing, stiffness, limited range of motion, joint inflammation, difficulty with stairs, pain arising from sitting and often hesitation to walk after rising from a sitting position.

A variety of noninvasive solutions for the treatment of pain, improvement in function and disability, and modification of the course of severe cartilage lesions and osteoarthritis have been proposed with variable success rates¹. Unfortunately, these treatments present many limitations. Pharmacologic management usually begins with analgesic and anti-inflammatory agents²; the large apparent variation in individual response to each drug, the absence of clear clinical data regarding therapeutic potential, and the drugs' possible side effects, represent limitations to their administration³. Topical agents have only been proven useful for short-term use for mild to moderate pain in joint degeneration⁴. Intra-articular injections of corticosteroids, as indicated by a few studies, are only of short-term benefit for pain and function⁵. New therapeutic approaches, such as the use of mesenchymal stem cells (MSC), seem to show promising preliminary results when applied in the context of joint degeneration and osteoarthritis⁶⁻¹⁰.

MSCs were first reported by A. Caplan in 1991¹¹. MSCs have extensive proliferative ability in culture in an uncommitted state, while retaining their multilineage differentiation potential, which makes them attractive candidates for biological cell-based tissue repair approaches^{12,13}. Over time, the actions of cells have changed our understanding of their nature and potential. The controversial and often poorly understood roles of MSCs are slowly being elucidated and the regenerative capabilities of fat (adipose derived stem cells, ADSCs), with mesenchymal properties, are being widely explored¹⁴⁻¹⁷.

Due to the importance of trophic mediation functions, Caplan coined a new name for the MSCs, as Medicinal Signaling Cells^{18,19}. Through trophic, mitogenic, anti-scarring, anti-apoptotic, immunomodulatory, and anti-microbial actions, produced by a plethora of bioactive elements, growth factors and cytokines, these cells "sense" and "signal" changes in the microenvironment where they reside¹⁸. More recently, perivascular cells (pericytes) have been reported as the originators of MSCs¹⁶. Adipose tissue is rich in vascular niches, that provide a readily available source of native cushioning, and could serve as a source of potential healing and regenerative tissue containing ADSCs^{20,21}. In this context,

perivascular cells activate and create changes in the microenvironment by serving as "a site-regulated drug store"¹⁸.

MSCs are multipotent cells (also called stromal multipotent cells), that possess the ability to differentiate into various tissues, such as bone, tendon, articular cartilage, ligaments, muscle and fat^{11,15}. Within bone marrow, MSCs associated with blood vessels, synovium, fat and muscle, can be mobilized for endogenous repair (as in the case of healing)^{17,22}. It has been established, that poor vascularization of the articular cartilage, the fibrocartilaginous meniscus and other joint structures, such as tendons, may be the reason these structures exhibit poor capabilities for repair²³. Adipose tissue, has been shown to secrete angiogenic factors, and may contribute to some of the positive outcomes reported in this and other studies using micro-fragmented adipose tissue²¹.

In the field of regenerative tissue-based biological treatments, the potential therapeutic effects are very promising. Various publications, presentations and training programs, show adipose tissue's use as a scaffold for other products, such as bone marrow-derived stem cell aspirates, platelet rich plasma, platelet lysates, hyaluronic acid, and even steroids. While the pioneers in advanced regenerative therapies deserve a debt of gratitude, it becomes difficult for the practitioner to assess what component is most beneficial, because there are many variations in the methods of treatment from one practitioner to another. What they have in common, are the potential benefits derived from cellular and biological medicine.

Adipose derived mesenchymal stem cells, are routinely obtained enzymatically from fat lipoaspirates as SVF, and/or may undergo prolonged *ex vivo* expansion, with significant senescence and decline in multipotency. These techniques have complex regulatory issues, and often lead to clinical results below expectations. The purpose of this study, is to measure the efficacy and potential benefits of using minimally manipulated (no enzymatic digestion or addition of other biological or pharmacological agents), micro-fragmented adipose tissue, in patients with severe worsening knee pain^{17,20,21,24-27}.

Our intention, is to show how micro-fragmented, micronized adipose tissue obtained with the new device Lipogems[®], administered using continuous ultrasound guidance, provides volume, support, cushioning, and potential healing and regenerative capabilities in a painful knee that has not responded to current treatment options.

CASE PRESENTATION

The patient is a 59-year-old male, with prior history of medial meniscus arthroscopic surgery 5 months before treatment. The knee pain did not respond and worsened after the arthroscopic surgery. The patient suffered pain while flexing the knee, walking, rising from sitting, exercising, and changing and maintaining positions. An MRI prior to arthroscopic surgery revealed a torn medial meniscus and medial osteoarthritis. The patient was not responsive to conservative treatment consisting of NSAIDS, physical therapy, steroid injections, or viscosupplementation injection using Hyalgan®.

MATERIALS AND METHODS

Pre-treatment targets were collated with current ultrasound images and historical MRI imaging, to determine the approximate amount of micro-fragmented volume of micronized fat necessary for injection. Ultrasound guidance was administered using a GE logiq P6 ultrasound unit with a 6-15 MHz linear probe. The patient was placed supine, and the skin overlying the abdomen was prepped with a Chlorhexidine gluconate 3.15% with isopropyl alcohol 70% solution and draped in the usual sterile fashion. A total of 120 ml of tumescent fluid prepared by diluting a 50ml of a 2% lidocaine solution with 1 ml of a 1mg per ml. epinephrine solution in 500ml normal saline was injected in the fat layer of the abdomen. Two small incisions were made with an 18 gauge needle 2 cm below the umbilicus and lateral to the midline of the abdomen to avoid penetrating the linea alba. The fluid was injected through the orifices and fanned in various directions using a 17 gauge blunt cannula. The fat was then harvested from both sides of the abdomen using a 13 gauge blunt cannula attached to a Vaculock 10 ml. syringe. The harvested fat was then introduced into the Lipogems® processing kit^{17,20}.

The Lipogems® system consists of a disposable kit for the aspiration, processing and reinjection of autologous adipose tissue in both human and veterinary medicine. Its core is a disposable and closed device, filled with saline solution that progressively reduces the size of the clusters of adipose tissue by means of mild mechanical forces, and special filters and eliminates pro-inflammatory oil and blood residues. The technique is gentle, and intra-operatively provides micro-fragmented micronized fat in a short time (30-45 minutes), without expansion and/or enzymatic treatment. The vasculo-stromal niches of Lipogems®, survive in the site of the injection and improve tissue health²⁰.

During the processing, the patient remained supine, and a bolster was placed under the knee for an approximately 40 degrees flexion. Findings from historical MRI images were noted, and targets mapped out. Multiple real-time ultrasound images were taken, and defects in the visible meniscal tissue targeted. The left knee joint was injected with 5 ml. of micro-fragmented processed fat, and the meniscus with 2 ml. of micro-fragmented processed fat. Each target was treated under continuous ultrasound image guidance, confirming needle placement. The joint compartment was injected using a lateral infrapatellar approach visualizing the fat filling the joint. Additional injections were directed at the anechoic defects in the meniscal echotexture, visualizing the micro-fragmented fat completely filling the soft tissue defects. The injection sites were cleaned and bandaged. No peri-procedural complications or adverse events were observed.

OUTCOME MEASURE

Pre- and post-treatment outcomes were determined using VAS pain scale, KOOS Knee Injury and Osteoarthritis Outcome Score, and post-treatment MRI.

Outcomes were taken immediately after the treatment, at 24 hours, 1 week, 5 weeks, 3 months, 6 months and 1 year (Figures 1-2).

RESULTS

In the immediate post injection period, there was a significant decrease in pain (Figure 1). This observation has been noted in other studies as well as other patients treated in this study, and is an interesting and unexpected outcome^{17,34}.

On a VAS pain scale of 1-10, with 10 being the worst pain, we observed an improvement from 8 to 0 at 1 year, with a rise to 4 at 3 months, and then a decline to 2 at 6 months. KOOS Knee Osteoarthritis and Outcome Score (0-100 scale, with 100 being perfect), increased from an initial score of 45 to 83 at 5 weeks, then declined to 73 at 3 months, and improved again to 96 at 6 months and 93 at 1 year.

The MRI 6 months after treatment, revealed improved signal and thickness of the cartilaginous tissue over the medial femoral condyle, and a widened joint space (Figure 3).

Meniscus changes are not comparable in the 6 month post treatment MRI as the patient underwent arthroscopic surgery of the meniscus following the original pre-treatment MRI.

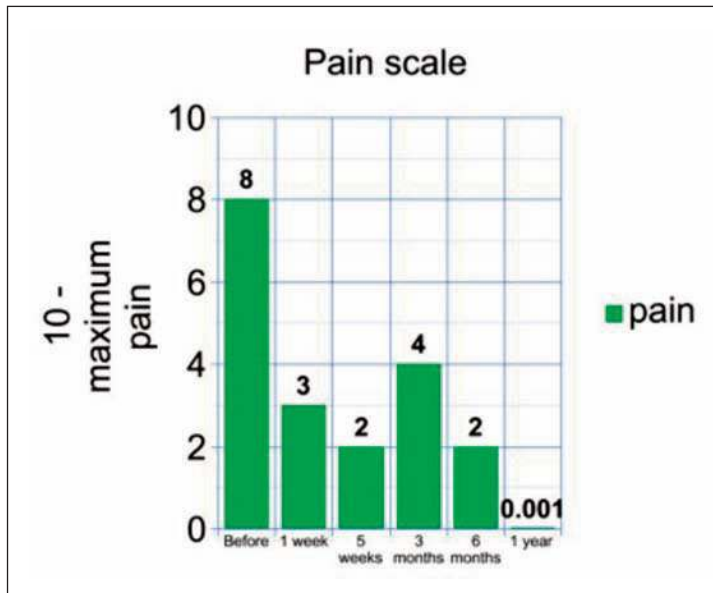


Figure 1. This graph displays the Knee Injury and Osteoarthritis Outcome Score (KOOS), which measures a score based on the patient’s conception of their knee and related problems. A perfect score for the KOOS is a 100.

DISCUSSION

The results from this case report demonstrate significant improvements in pain and quality of life, as well as the appearance of increased cartilaginous tissue as indicated by MRI imaging at 6 months after treatment. No adverse events were observed. In addition, the treatment with micro-fragmented fat provided cushion, volume, support, and filling of soft tissue defects as previously reported^{13-15,17,19,22}. Micro-fragmented fat, has been shown to have intact stromal vascular niches harboring cellular elements with mesenchymal stem cell²⁷ and pericyte characteristics^{20,16}, and these attributes may play an important role in the achieved

benefits^{28,29}. In addition, micro-fragmented clusters contain small-sized, intact adipocytes that may play an important role in cell signaling.

The positive clinical outcome, as indicated by the potential repair and regeneration of the cartilage is very promising^{28,29}. Adipose tissue has been positively highlighted in different studies detailing a cascade of events including signaling, trophic, immunomodulatory, mitogenic, anti-microbial, anti-scarring, and anti-apoptotic properties that contribute to potential regenerative mechanisms^{11,13,22,30-32}. While more studies are required to validate the effectiveness of this approach for the treatment of knee pain, this data is very encouraging.

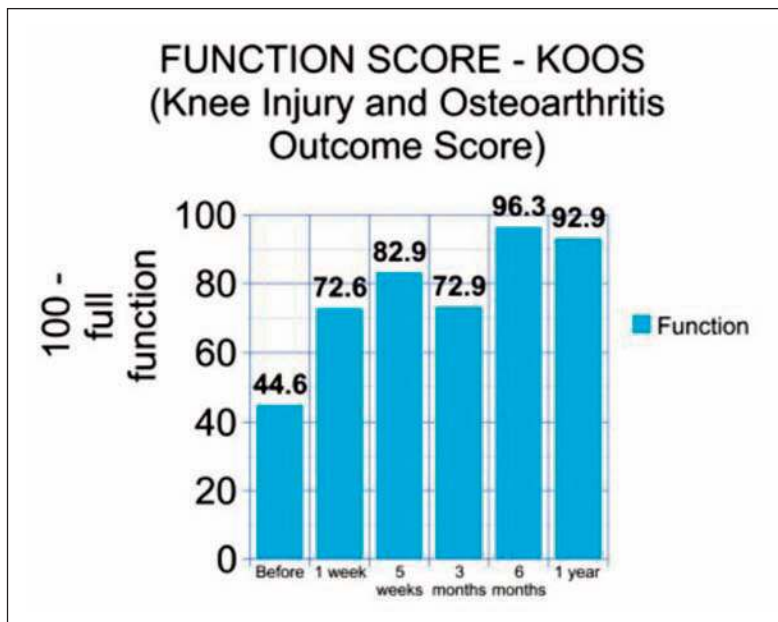


Figure 2. This graph displays the Visual Analog Scale (VAS), which measures the pain intensity of the joint that is being treated. It runs on a scale from 0 to 10, with 0 being no pain and 10 being the worst pain.

Theories as to mechanism of action may include the micro-fragmented adipose tissue providing volume, support, cushioning, filling of soft tissue defects or potential healing and regenerative capabilities. Additional mechanisms may include direct differentiation and chondrogenesis¹⁵, regenerative signaling by activated perivascular cells¹⁶, tissue repair²², signaling of trophic and paracrine factors¹⁹, activation of opioid receptors³⁰, pain reduction^{17,30}, down-regulation of the arthrogenic muscle inhibition³³, exosome initiated cascades³² or a combination of all of these.

The improvement in measured outcomes for pain, quality of life, KOOS (Knee Injury and Osteoarthritis Outcome Score), and MRI imaging showing sustained gains up to 6 months, support these concepts. Additional outcome scoring including quadriceps strength and range of motion of the injected joint have been added to subsequent patient data in our study.

Based on this case report, the investigators are encouraged to continue with clinical studies to test and confirm the efficacy of micro-fragmented adipose tissue in the treatment of knee pain, thus filling the vast void of treatment options for the painful knee after the initial diagnosis of degeneration. Indeed, for patients who fail conventional treatments, and do not want or are not candidates for surgery,

there are very few if any options. These positive outcomes potentially open the door to a viable alternative therapy.

CONCLUSIONS

Although this is a single case report, part of a larger study, and not a randomized controlled trial, the results are very encouraging. The initial 20 cases will now be included as part of a larger IRB study of 100 cases, as the expanded cohort has been approved by IRCM. The autologous, micro-fragmented adipose tissue obtained with the new device Lipogems[®] and administered under continuous ultrasound guidance, appears to be a safe and effective treatment of knee pain in patients with multi-component abnormalities that are not responsive to other current treatments.

ACKNOWLEDGMENTS:

Carlo Tremolada, MD for training. Barbara Krutchkoff for help designing the IRB study, and editing the paper. Silvia Versari for help editing the paper.

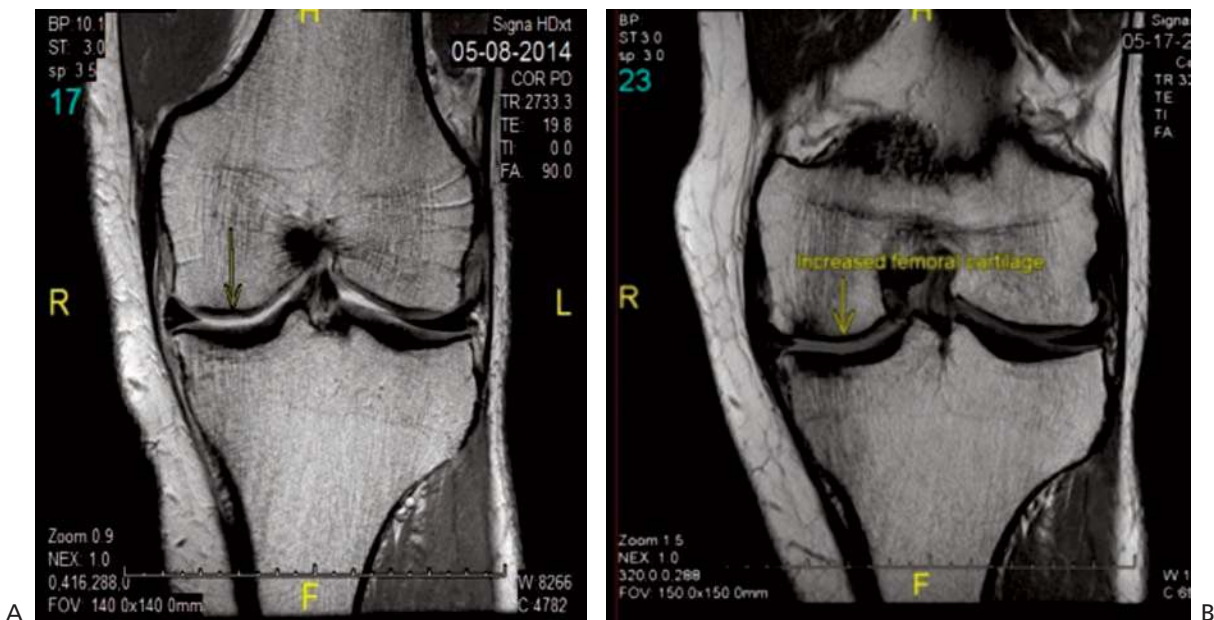

Figure 3. A, MRI prior to treatment revealing medial compartment degeneration (arrow). B, MRI 6 months after treatment with widening of the joint space and improved signal and thickness of the cartilaginous tissue (yellow arrow). MRI prior to treatment reveals a thinning articular cartilage measured by Radiologist to be 0.75 mm. MRI taken 6 months post treatment reveals an improved thickened articular cartilage measured by Radiologist at 1.5 mm of cartilage.

REFERENCES

- Hayami T. Osteoarthritis of the knee joint as a cause of musculoskeletal ambulation disability symptom complex (MADS). *Clin Calcium* 2008; 18: 1574-1580.
- Hochberg MC, Altman RD, Brandt KD, Clark BM, Dieppe PA, Griffin MR, Moskowitz RW, Schnitzer TJ. Guidelines for the medical management of osteoarthritis. *Arthritis Rheum* 1995; 38: 1535-1540.
- Zhang W, Moskowitz R, Nuki G, Abramson S, Altman R, Arden N, Bierma-Zeinstra S, Brandt KD, Croft P, Doherty M, Dougados M, Hochberg M, Hunter DJ, Kwoh K, Lohmander LS, Tugwell P. OARSI recommendations for the management of hip and knee osteoarthritis, Part II: OARSI evidence-based, expert consensus guidelines. *Osteoarthr Cartilage* 2008; 16: 137-162.
- Niethart FU, Gold MS, Solomon GS, Liu J-M, Unkauf M, Albrecht HH, Elvik F. Efficacy of topical diclofenac diethylamine gel in osteoarthritis of the knee. *J Rheumatol* 2005; 32: 2384-2392.
- Østergaard M, Halberg P. Intra-articular corticosteroids in arthritic disease: a guide to treatment. *BioDrugs* 1998; 9: 95-103.
- Koh YG, Choi YJ, Kwon OR, Kim YS. Second-look arthroscopic evaluation of cartilage lesions after mesenchymal stem cell implantation in osteoarthritic knees. *AM J Sport Med* 2014; 42: 1628-1637.
- Koh Y-G, Choi Y-J. Infrapatellar fat pad-derived mesenchymal stem cell therapy for knee osteoarthritis. *The Knee* 2012; 19: 902-907.
- Wu L, Cai X, Zhang S, Karperien M, Lin Y. Regeneration of articular cartilage by adipose tissue derived mesenchymal stem cells: perspectives from stem cell biology and molecular medicine. *J Cell Physiol* 2013; 228: 938-944.
- Buda R, Vannini F, Cavallo M, Baldassarri M, Luciani D, Mazzotti A, Pungetti C, Olivieri A, Gianniniet S. One-step arthroscopic technique for the treatment of osteochondral lesions of the knee with bone-marrow-derived cells: three years results. *Musculoskelet Surg* 2013; 97: 145-151.
- Buda R, Vannini F, Cavallo M, Grigolo B, Cenacchi A, Giannini S. Osteochondral lesions of the knee: a new one-step repair technique with bone-marrow-derived cells. *J Bone Joint Surg* 2010; 92(Suppl. 2): 2-11.
- Caplan AI. Mesenchymal stem cells. *J Orthop Res* 1991; 9: 641-650.
- Tremolada C, Beltrami G, Magri A, Bianchi F, Ventura C, Di Vito C, Campanella R, Navone S, Marfia G, Caplan Ai. Adipose mesenchymal stem cells and “regenerative adipose tissue graft” (Lipogems™) for musculoskeletal regeneration. *Eur J Musculoskelet Dis* Submitted.
- Augello A, Kurth TB, De Bari C. Mesenchymal stem cells: a perspective from in vitro cultures to in vivo migration and niches. *Eur Cell Mater* 2010; 20: 121-133.
- Pak J, Lee JH, Lee SH. Regenerative repair of damaged meniscus with autologous adipose tissue-derived stem cells. *BioMed Res Int* 2014; 2014: 436029.
- Cai Z, Pan B, Jiang H, Zhang L. Chondrogenesis of Human Adipose-Derived Stem Cells by In Vivo Co-graft with Auricular Chondrocytes from Microtia. *Aesthet Plast Surg* 2015; 39: 431-439.
- Crisan M, Yap S, Casteilla L, Chen C-W, Corselli M, Park TS, Andriolo G, Sun B, Zheng B, Zhang L, Norotte C, Teng PN, Traas J, Schugar R, Deasy BM, Badylak S, Bühring HJ, Jacobino JP, Lazzari L, Huard J, Péault B. A perivascular origin for mesenchymal stem cells in multiple human organs. *Cell Stem Cell* 2008; 3: 301-313.
- Raffaini M, Tremolada C. Micro Fractured and Purified Adipose Tissue Graft (Lipogems®) Can Improve the Orthognathic Surgery Outcomes Both Aesthetically and in Postoperative Healing. *CellR4* 2014; 2: e1118.
- Caplan AI, Correa D. The MSC: an injury drugstore. *Cell Stem Cell* 2011; 9: 11-15.
- Caplan AI, Dennis JE. Mesenchymal stem cells as trophic mediators. *J Cell Biochem* 2006; 98: 1076-1084.
- Bianchi F, Maioli M, Leonardi E, Olivi E, Pasquinelli G, Valente S, Mendez AJ, Ricordi C, Raffaini M, Tremolada C, Ventura C. A new nonenzymatic method and device to obtain a fat tissue derivative highly enriched in pericyte-like elements by mild mechanical forces from human lipoaspirates. *Cell Transplant* 2013; 22: 2063-2077.
- Tassinari R, Canaider S, Pasquinelli G, Tremolada C, Ventura C. Lipogems, a New Modality of Fat Tissue Handling to Enhance Tissue Repair in Chronic Hind Limb Ischemia. *CellR4* 2014; 2: e1289.
- Di Marino AM, Caplan AI, Bonfield TL. Mesenchymal stem cells in tissue repair. *Front Immun* 2013; 4: 201.
- Ruiz-Ibán MÁ, Díaz-Heredia J, García-Gómez I, Gonzalez-Lizán F, Elías-Martín E, Abaira V. The effect of the addition of adipose-derived mesenchymal stem cells to a meniscal repair in the avascular zone: an experimental study in rabbits. *Arthroscopy* 2011; 27: 1688-1696.
- Canaider S, Maioli M, Facchin F, Bianconi E, Santaniello S, Pigliaru G, Ljungberg L, Burigana F, Bianchi F, Olivi E, Tremolada C, Biava PM, Ventura C. Human Stem Cell Exposure to Developmental Stage Zebrafish Extracts: a Novel Strategy for Tuning Stemness and Senescence Patterning. *CellR4* 2014; 2: e1226.
- Maioli M, Rinaldi S, Santaniello S, Castagna A, Pigliaru G, Delitala A, Bianchi F, Tremolada C, Fontani V, Venturat C. Radioelectric asymmetric conveyed fields and human adipose-derived stem cells obtained with a nonenzymatic method and device: a novel approach to multipotency. *Cell Transplant* 2014; 23: 1489-1500.
- Tremolada C, Palmieri G, Ricordi C. Adipocyte transplantation and stem cells: plastic surgery meets regenerative medicine. *Cell Transplant* 2010; 19: 1217-1223.
- Carelli S, Messaggio F, Canazza A, Hebda DM, Caremoli F, Latorre E, Grimoldi MG, Colli M, Bulfamante G, Tremolada C, Di Giulio AM, Gorio A. Characteristics and Properties of Mesenchymal Stem Cells Derived from Micro-fragmented Adipose Tissue. *Cell Transplant* 2015; 24: 1233-1252.
- Giori A, Tremolada C, Vailati R, Navone S, Marfia G, Caplan A. Recovery of Function in Anal Incontinence After Micro-Fragmented Fat Graft (Lipogems®) Injection: Two Years Follow Up of the First 5 Cases. *CellR4* 2015; 3: e1544.
- Benzi R, Marfia G, Bosetti M, Beltrami G, Magri A, Versari S, Tremolada C. Microfractured Lipoaspirate May Help Oral Bone and Soft Tissue Regeneration: a Case Report. *CellR4* 2015; 3: e1583.
- Guo W, Wang H, Zou S, Gu M, Watanabe M, Wei F, Dubner R, Huang JT, Ren K. Bone Marrow Stromal Cells Produce Long Term Pain Relief in Rat Models of Persistent Pain. *Stem Cells* 2011; 29: 1294-1303.

31. Diekman BO, Rowland CR, Lennon DP, Caplan AI, Guilak F. Chondrogenesis of adult stem cells from adipose tissue and bone marrow: induction by growth factors and cartilage-derived matrix. *Tissue Eng Part A* 2009; 16: 523-533.
32. García-Contreras M, Messaggio F, Jimenez O, Mendez A. Differences in exosome content of human adipose tissue processed by non-enzymatic and enzymatic methods. *CellR4* 2014; 3: e1423.
33. Keller K, Engelhardt M. Arthrogenic muscle inhibition after trauma-is there an age dependency of the intensity of arthrogenic muscle inhibition? *Sportverletz Sportschaden* 2014; 28: 199-203.
34. Slynarski K. Treatment of knee osteoarthritis by micro-fragmented adipose tissue. 12th World Congress of the International Cartilage Repair Society, Chicago May 8-11, 2015.