

Adipose Tissue Derived Mesenchymal Stem Cell Therapy for the Treatment of Chondral Lesions in The Hip.

A 2 years follow-up comparison study with microfractures.

Dr. A. Fontana – Dir. Ortop 1 – COF Lanzo Hospital – Como - Italy

Introduction:

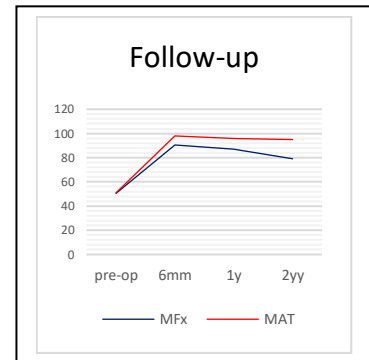
We here report a retrospective comparative analysis of consecutive patients from a single centre, affected by FAI and all treated with microfracture (MFx) or micro-fragmented autologous adipose tissue transplantation (MAT) technique, between 2014 and 2015.

Methods:

INCLUSION CRITERIA	EXCLUSION CRITERIA
<ul style="list-style-type: none">• Age between 18 and 55 yy.• Acetabular chondral lesion grade III and IV.• Chondral lesions size 2-8 cm².• radiological degenerative changes < 2 (Tonnis class).	<ul style="list-style-type: none">• Rheumatoid arthritis.• Dysplasia.• Axial deviation of the femoral neck.• Coxa profunda.• Protrusio acetabuli.

Between 2014 and 2015, 226 patients with FAI underwent an arthroscopic treatment of an acetabular chondral lesion and were treated with either MFx or MAT. Of the 226 subjects, 194 fulfilled the inclusion/exclusion criteria of the study.

Of the 194 eligible patients, 77 (45 male, 32 female) were treated with arthroscopic MFx and 117 (63 male, 54 female) with arthroscopic MAT. Patients were evaluated pre- and post-operatively by the modified Harris Hip Score (mHHS) at 6 months, 1 and 2 years' follow-up. Mean patient age at surgery was 38±10 (19-54 years) for MFx and 39±9 (18-50 years) for MAT; mean lesion size was 3.6±1.4 cm² (2-8 cm²) for MFx and 3.2±1.5 cm² (2-8 cm²) for MAT.



Results:

Baseline mHHS was 48±5 for MFx and 48±6 for MAT. Both MFx and MAT significantly improved the clinical status at 6 months (mHHS 86±9/MFx - 94±8/MAT) and 1 year (mHHS 84±6/MFx - 94±4/MAT). Over the 2 years period, a progressive decrease in functionality was measured in the MFx group, while the positive outcomes of the MAT group remained stable (mHHS 75±8/MFx - 92±6/MAT).

No conversion to total hip arthroplasty (THA) was observed in the MAT group, whereas THA was necessary in 10 (7.8%) of the patients of the MFx group.

Discussion:

This is the first study comparing the clinical outcome of using MFx and MAT in the treatment of FAI-induced acetabular chondral defects that reached the 2-year follow-

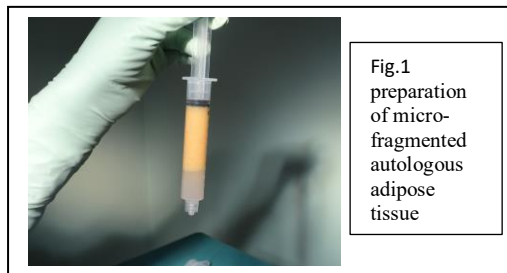


Fig.1 preparation of micro-fragmented autologous adipose tissue

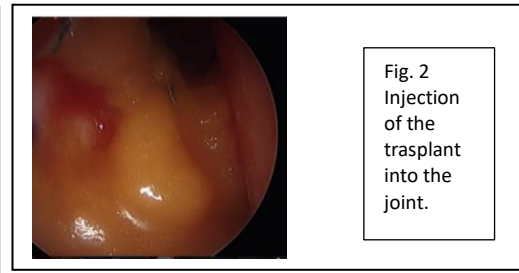


Fig. 2 Injection of the trasplant into the joint.

up. MFx is still the treatment of choice for small chondral defects of the acetabulum and femoral head. Satisfactory clinical results after MFx for lesions in the hip have been recently reported. Although MFx has been shown to be effective, after a mean of two years a deterioration in the function has been reported. In this context, MAT appears to give satisfactory results. It exploits the regenerative potential of mesenchymal progenitor cells naturally contained in the adipose tissue. Adipose tissue is rich in vascular niches that provide a readily available source of native mesenchymal cells, and could serve as a source of potential healing and regenerative tissue. This effect is supported by evidence of adipose derived bioactive units promoting the chondrogenic differentiation of mesenchymal stem cells and maintaining chondrocyte phenotype.

STUDY LIMITATIONS:
<ul style="list-style-type: none">• Retrospective observational study.• Patients were not randomised.• Clinical outcome was only assessed using the mHHS.

Significance:

The results of this study provide proof that MAT approach is safe and improves the clinical outcomes when associated with the arthroscopic repair of an acetabular chondral damage. The MAT group showed long-term improvement and scoring significantly better than the MFx group over the 2-year period.