

Technical Note

Adipose-Derived Stem Cell Transplant Technique for Degenerative Joint Disease

Ryan P. Coughlin, M.D., F.R.C.S.C., Alexander Oldweiler, B.S., Dayne T. Mickelson, M.D., and Claude T. Moorman III, M.D.

Abstract: The treatment of mild to moderate osteoarthritis can be a challenging problem for orthopaedic surgeons. As new research and treatment strategies have emerged, stem cell therapy has risen in popularity for the management of degenerative joint conditions. In this article, we describe a stepwise technical approach with tips and pearls to performing adipose-derived stem cell transplantation for degenerative joint disease of the knee.

The incidence of osteoarthritis in the young, active population has become increasingly more common.¹ Treating this demographic can be challenging, as more definitive solutions, such as total joint arthroplasties, can lead to less than desirable outcomes, with implant longevity being a serious concern.² Furthermore, these procedures can place undesirable activity limitations on patients who continue to desire high levels of function. As the search for new innovative strategies continues, intra-articular stem cell injections have become increasingly more common in the treatment of degenerative joint disease.

Stem cell therapies take advantage of the multipotent properties of mesenchymal stem cells (MSCs) such as their ability to differentiate into chondrocytes.^{3,4} Stem cells that are currently used are derived from either bone marrow or adipose tissue. This article discusses the step-by-step approach to performing an adipose-derived stem cell (ADSC) transplant technique for degenerative joint

disease of the knee (Video 1). The described technique uses an enzyme-free method of processing the lipos aspirate extracted via minimally invasive liposuction.^{5,6} A nonexpanded adipose tissue product is produced by this process, which contains human adipose stem cells (or stromal cells) and pericytes. This technology works through mild mechanical tissue cluster size reduction in a full immersion, closed system, which avoids the need for additional processing or equipment (i.e., centrifugation and subfractional harvesting).⁵

Surgical Technique

Patient Positioning and Sterile Draping

The patient is positioned supine. Prophylactic antibiotics are given intravenously prior to skin incision. Although a tourniquet is placed around the upper thigh of the operative extremity, it is not routinely inflated. The abdominal area and lower extremity (in Video 1, both lower extremities are prepped for bilateral knee injections) are prescrubbed using Hibiclens (Mölnlycke Health Care, Gothenburg, Sweden) and 70% U.S.P. isopropyl alcohol (Hydrox Laboratories, Elgin, IL) and prepped using Chloraprep (Becton, Dickinson and Company, Franklin Lakes, NJ). Sterile 1015 U-drapes (Steri-Drape; 3M, St. Paul, MN) are placed just distal to the tourniquet and around the prepped area of the flanks and abdomen. Sterile split drapes are then used to drape the abdominal area free followed by an extremity drape. A rectangular area is cut in the extremity drape to expose the abdominal area. Four strips of 3M Ioban 2 Antimicrobial Incise Drapes are used to seal the operative field along the perimeter of the cut-out section in the extremity drape (Fig 1A).

From the Department of Orthopaedic Surgery (R.P.C., D.T.M.) and Duke Center for Integrated Medicine (A.O., C.T.M.), Duke University, Durham, North Carolina, U.S.A.

The authors report the following potential conflicts of interest or sources of funding: C.T.M. receives support from Lipogems, Smith and Nephew, Moorman Medical Consulting, Pivot, SMV, Breg, Mitek, and Arthrex. Full ICMJE author disclosure forms are available for this article online, as [supplementary material](#).

Received January 17, 2017; accepted June 27, 2017.

Address correspondence to Ryan P. Coughlin, M.D., F.R.C.S.C., Division of Orthopaedic Surgery, Duke University, 3475 Erwin Rd, Durham, NC 27705, U.S.A. E-mail: ryan.coughlin@duke.edu

© 2017 by the Arthroscopy Association of North America. Published by Elsevier. This is an open access article under the CC BY-NC-ND license (<http://creativecommons.org/licenses/by-nc-nd/4.0/>).

2212-6287/1781

<http://dx.doi.org/10.1016/j.eats.2017.06.048>

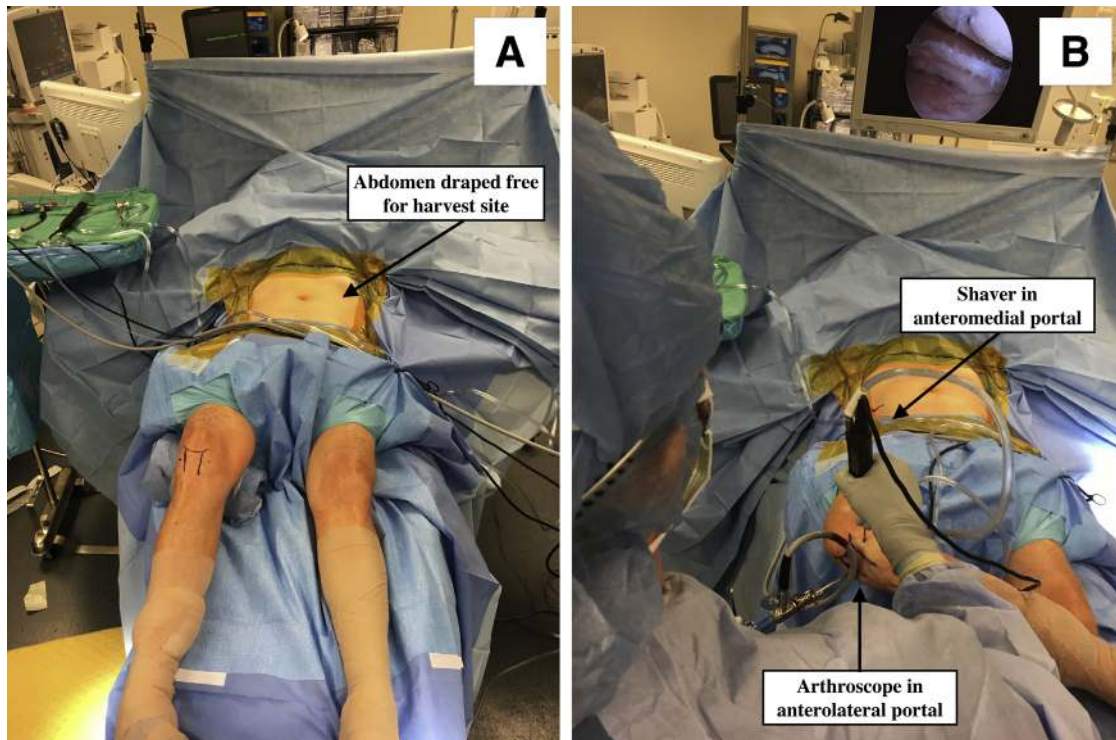


Fig 1. (A) Patient is positioned supine with the abdomen and flanks freely exposed. The patient is prepped and draped using an extremity drape with a cut-out section for the abdominal harvest site. (B) An arthroscopy is performed on the right knee while the tumescent solution acts to emulsify the subcutaneous fat for subsequent lipoaspiration.

Adipose Tissue Emulsification

The right flank area is injected with 1% xylocaine with epinephrine to create a small skin wheal. An 11-blade scalpel is used to make a stab incision in the subcutaneous tissue. The tumescent solution, which is premixed by our pharmacy, contains 25 mL of 2% lidocaine and 0.5 mL epinephrine (1:1,000) in a 250-mL bag of normal saline. This solution is injected subcutaneously using a 17 gauge cannula. Sixty milliliters of solution are injected below the umbilicus and 60 mL above the umbilicus. Gentle agitation of the tissue using a hacking tapotement technique is completed followed by a 10-minute resting period to allow for adequate emulsification.

During this time, we perform the knee arthroscopy (Fig 1B). The arthroscope is introduced into the knee through a standard anterolateral viewing portal. An anteromedial portal is created under direct vision, using a spinal needle for localization. The knee is then systematically examined, beginning with the suprapatellar pouch and proceeding in a standard fashion. Any reactive synovitis is debrided. The knee is inspected for meniscal tears, loose bodies, chondral flaps, and any pathology that needs to be appropriately addressed.

Adipose Tissue Harvesting

The adipose tissue is then harvested with the liposuction cannula LGI 13 gauge \times 185 mm connected to a

10-mL Vaclok syringe (Lipogems International, Milan, Italy; Fig 2A). This syringe allows the plunger to lock, creating a negative pressure vacuum. Liposuction of abdominal fat is performed using brisk broad strokes until a total of 80 to 120 mL of aspirate is obtained depending on the patient's body habitus. With each successive liposuction attempt, the Vaclok syringes become pinker in color, indicating a more hemorrhagic aspirate with less adipose tissue yield (Fig 2 B and C). The adipose tissue from each of the Vaclok syringes is transferred to a single 60-mL syringe using a luer lock connector (Fig 2D).

Stem Cell Processing

The processing cylinder (Lipogems) containing the 5 stainless steel marbles is connected to 2 hoses. The hose attached to the blue or orange size reduction filter (depending on the cylinder size used: blue for small and orange for large) is connected to a bag of normal saline. The gray size reduction filter on the opposite end of the cylinder is attached to a hose connected to a waste bag, which rests on the floor. The cylinder is then rotated so that the gray filter points upward. Both the blue/orange filter hose and waste hose are opened to allow the cylinder to fill with normal saline while holding it vertically and shaking intermittently to remove air bubbles. Both hoses are then clamped closed once the cylinder is filled completely. The 60-mL syringe containing the lipoaspirate is connected

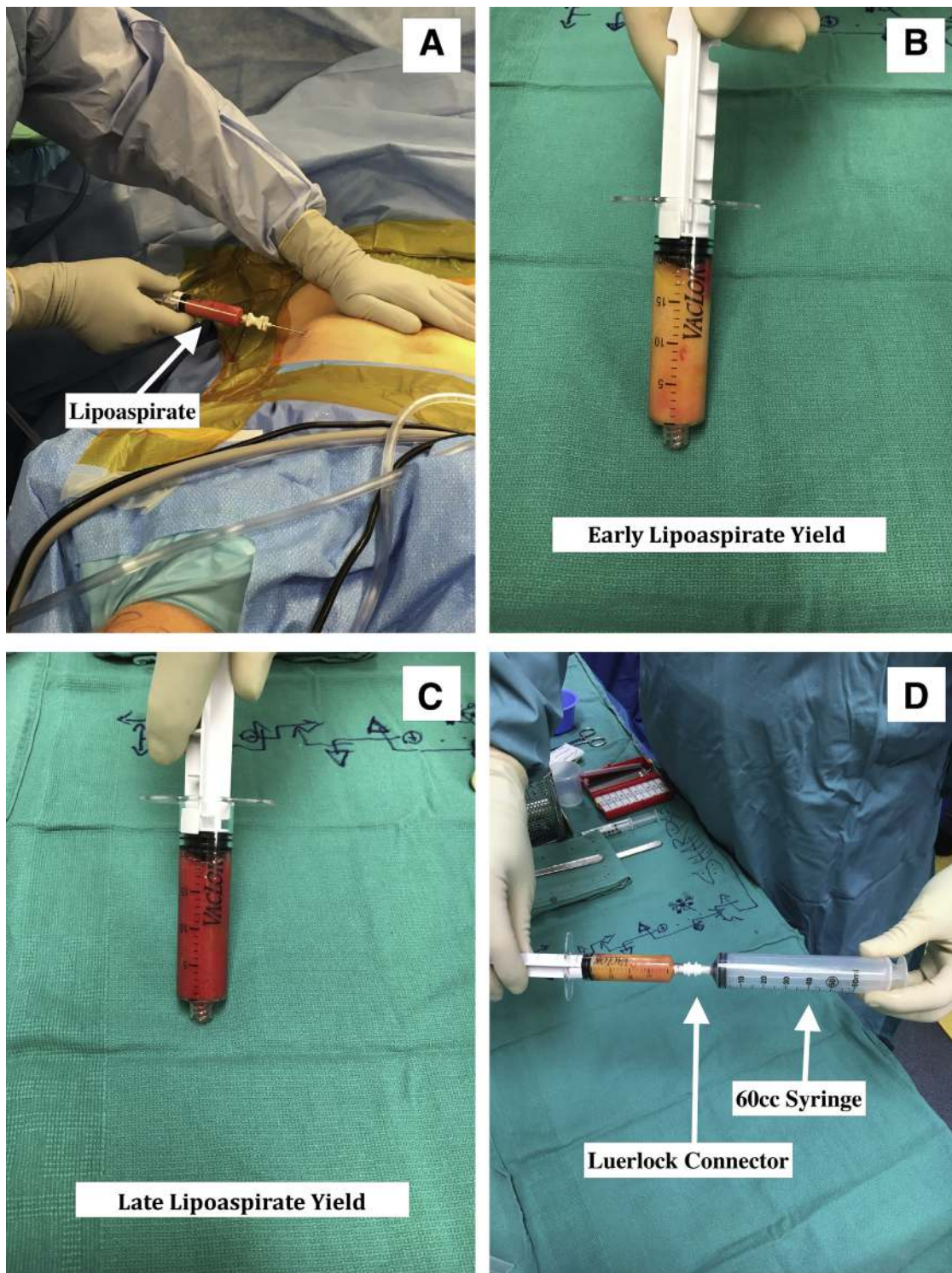


Fig 2. (A) Lipoaspiration is being performed using the Vaclok syringe that creates a negative suction seal. (B) Vaclok syringe showing a yellow lipoaspirate obtained from the first liposuction attempt. (C) Vaclok syringe showing a more hemorrhagic lipoaspirate from later liposuction attempts, indicating less adipose tissue yield. (D) Successive lipoaspirates are combined into a single 60-mL holding syringe using the luerlock connector.

to the blue/orange filter. The adipose tissue is injected into the processing cylinder through the blue/orange filter with the clamp on the gray waste side open. With the blue/orange filter pointing up, both clamps are

opened to allow for rinsing or elimination of blood and oily impurities into the waste bag. Once the fluid is transparent, the shaking process will begin (Fig 3 A and B). Both hoses are clamped closed, and the

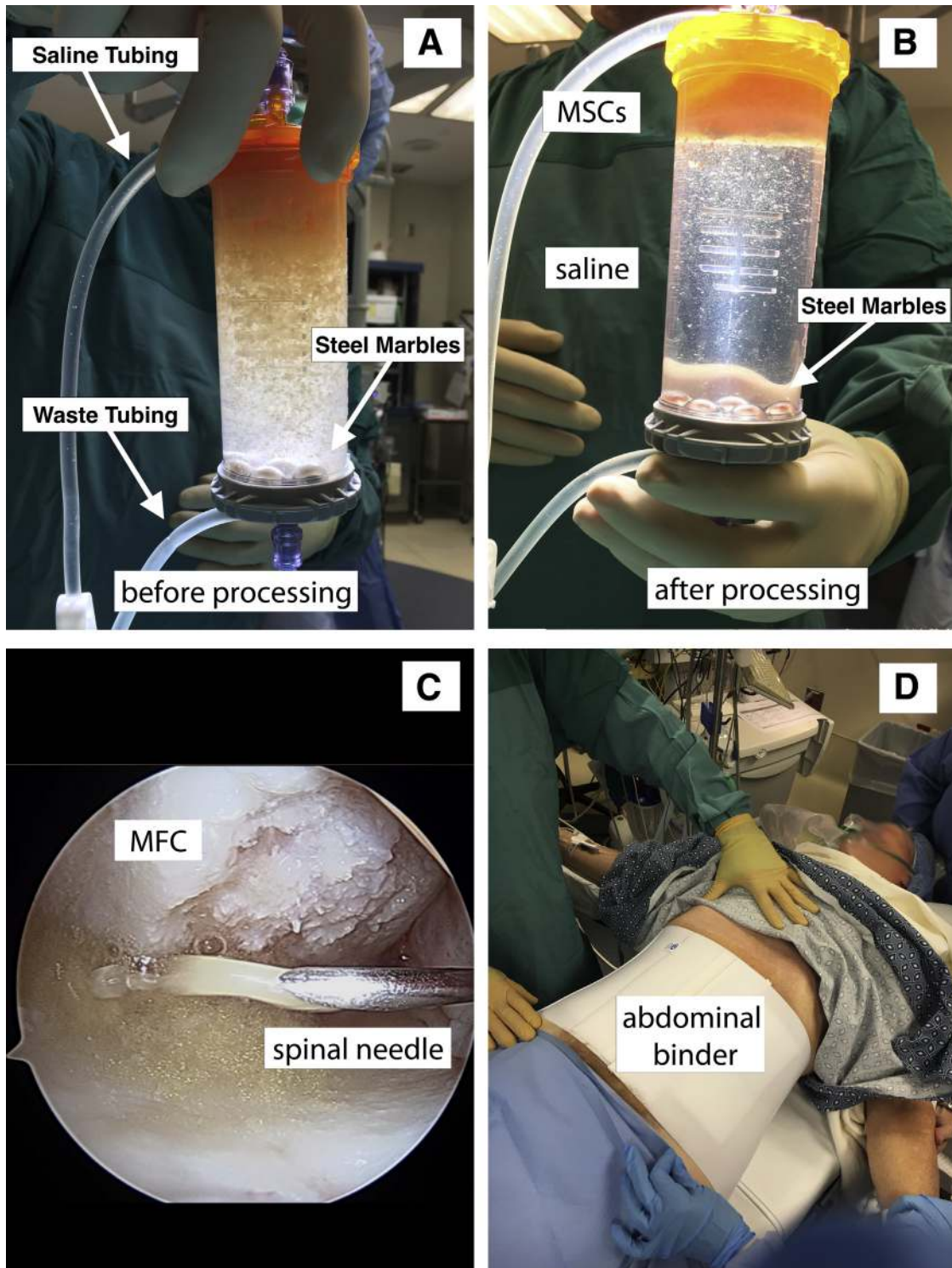


Fig 3. (A) Cylinder containing the steel spheres used for mechanical processing of the lipoaspirate. The top hose attached to the orange filter is connected to a bag of normal saline. The bottom hose attached to the gray filter is connected to a waste bag. The cylinder containing normal saline and the lipoaspirate is ready for processing. (B) After processing is complete, the blood and oily impurities have been washed away, leaving a layer of mesenchymal stem cells (MSCs) at the top and saline solution below. (C) The MSCs are being injected using a spinal into the medial compartment under arthroscopic visualization. A full-thickness cartilage defect is seen on the medial femoral condyle (MFC). The knee had been drained of all fluid before injection. (D) An abdominal binder is applied for 48 hours to help minimize swelling and ecchymosis.

Table 1. Technical Tips and Pitfalls to Performing Adipose-Derived Stem Cell Transplant for Degenerative Joint Disease

Tips and Pearls	Pitfalls
Tumescent solution injection followed by hacking tapotement technique to promote emulsification.	Preoperative screen for abdominal hernias and scars to avoid injury to abdominal contents during lipoaspiration.
Three saline washes combined with 2 30-second rounds of mixing for ideal mechanical processing and cellular filtration.	Sequential harvest site order in patients with low percentage body fat: below umbilicus, above umbilicus, flanks, and buttocks.
Permit sedimentation of stem cells to decant excess fluid.	Swelling and ecchymosis minimized by application of abdominal binder for 48 hours postoperatively.
Drain arthroscopy fluid before stem cell injection.	

cylinder is shaken for 30 seconds to allow the action of the steel spheres to emulsify and microfracture the adipose tissue. This sequence is repeated followed by a final wash.

Two 10-mL luer lock syringes are connected to both sides of the chamber in order to allow removal of the stem cell product. The processing cylinder is flipped with the gray filter at the top. The blue/orange filter hose is opened. Through the syringe connected to the blue/orange filter a full 10 mL of saline is drawn. The blue/orange filter hose is closed. The cylinder is held vertically with the gray filter at eye level. Acting on the syringe connected to the blue/orange filter, the saline is pushed into the cylinder, thus forcing the stem cell product through the gray filter into the empty syringe connected on top. The top syringe containing the stem cells is removed and placed facing up to allow the cells to settle within the syringe and separate from the excess fluid. The cylinder is shaken slightly, and the process is repeated to continue retrieving the cells. This is performed until no more cells are yielded from the cylinder. It is normal that some fibrous tissue remains in the cylinder after processing. The individual syringes that were left standing on the back table are decanted, removing the excess fluid that has separated from the stem cells. The cells are then combined into one syringe using a white luer lock connector. The goal is to obtain 10 mL of final stem cell product for injection into a large joint.

Stem Cell Injection

Next, the anteromedial portal is closed with an Anderson stitch while the arthroscope remains in the lateral viewing portal. A spinal needle is then introduced into the medial compartment. The trocar from the spinal needle is removed, and the arthroscopy fluid is turned off. The suction tubing is connected to the spinal needle until the knee joint is dry. The syringe containing 10 mL of adipose-derived stems cells is connected to the spinal needle and injected into the

knee under direct visualization (Fig 3C). The scope is removed, and the lateral portal is quickly closed to prevent the stem cells from leaking through the open portal. The knee is then taken through 10 cycles of gentle flexion-extension to help disperse the stem cells evenly throughout the knee. A sterile compression dressing is applied.

In this case example, we elected to inject the contralateral knee with stem cells as well. An 18-gauge needle is introduced into the suprapatellar pouch, and 10 mL of the stem cells are injected into the knee. The knee is gently ranged similarly to the contralateral knee to help distribute the stem cell products.

A simple suture using 3-0 nylon is used to close the abdominal harvest site incision, and a sterile dressing is applied. An abdominal binder is applied for 48 hours to minimize swelling and ecchymosis (Fig 3D). Postoperatively, the patient is weight bearing as tolerated with no activity restrictions.

Discussion

MSCs have traditionally been harvested from cancellous bone of the iliac crest, proximal tibia, or calcaneal tuberosity producing bone marrow aspirate concentrate (BMAC). Although aspirating iliac bone marrow stem cells poses less morbidity than traditional tricortical iliac crest graft techniques, the potential for serious donor site complications still exists.⁷ Adipose tissue has been shown to contain a greater MSC population density than BMAC. MSCs account for one in 25,000 to 100,000 cells in BMAC, while MSCs account for 2% of the entire cell population of the lipoaspirate.⁵ Adipose tissue contains 500 times more pluripotent cells than the equivalent volume of bone marrow aspirate.³ MSCs harvested from adipose tissue must undergo processing before injection into the target site. Some of the most recent technologies for processing adipose tissue for reinjection are the Puregraft (Solana Beach, CA) and Tulip Medical Products

Table 2. The Advantages and Disadvantages/Limitations of Adipose-Derived Stem Cell Therapy for Osteoarthritis

Advantages	Disadvantages
Largely dispensable tissue and readily accessible.	Limited proliferation and differentiation potential in comparison with pluripotent stem cells.
Minimal morbidity.	Techniques to optimize cell purity and increase sorting efficiency are needed.
Uncultured cells with no ex vivo expansion, minimizing risk of infection and immunogenicity.	Randomized control trials are needed to better understand patient outcomes.
Well-vascularized tissue with abundant pericytes.	
Immunosuppressive actions, privileged properties, anti-inflammatory effects.	
Clinical applications for both focal cartilage defects and generalized osteoarthritis.	

(San Diego, CA). These technologies use gravity separation, Colman fat centrifugation, and microfat techniques. We feel the Lipogems ADSC product is simple to isolate and may provide greater tissue viability, as well as a lower percentage of contaminants.⁶ Table 1 highlights the technical tips and pearls and pitfalls of our technique.

Stem cell therapy is an emerging technology in the treatment of osteoarthritis. ADSCs have been shown to have benefits that are 2-fold in laboratory testing: (1) direct differentiation into chondrocytes^{4,6} and (2) an anti-inflammatory response suppressing both cytokines and the inhibition of immune cells.³ Furthermore, the harvesting of lipid-derived stem cells through this system is rich in pericytes. The pericytes have the unique advantage of promoting vascular endothelial growth, form vascular branches, guide sprouting branches, elicit vascular smooth muscles, and exhibit macrophage-like activities.⁸ Basic science research on ADSC therapy for osteoarthritis has been primarily focused on animal models. In an osteoarthritic rabbit model, ADSCs decreased the progression of cartilage degeneration and osteophyte formation compared with the control group.⁹ Labeled ADSCs injected into an osteoarthritic sheep model had the ability to populate areas of damaged cartilage and slow the progression of osteoarthritis.¹⁰ Clinical studies performed in human subjects with osteoarthritis have shown promising early results. Patients with knee osteoarthritis undergoing arthroscopic debridement were injected with autologous ADSCs prepared in platelet-rich plasma. Treated patients showed improved mobility and function and reduced pain scores.¹¹ At 2-year follow-up, patients had significantly improved Western Ontario and McMaster Universities Osteoarthritis pain scores, visual analog scale pain scores, and cartilage regeneration on advanced imaging studies.¹² In a prospective randomized clinical trial comparing microfracture (MFX) and ADSCs with MFX alone, knee cartilage defects treated with MFX and ADSCs showed significant improvement in radiographic and Knee Injury and Osteoarthritis Outcome Score pain and symptoms subscores. However, no difference was seen in activity, sports, and quality-of-life subscores.¹³ The advantages and disadvantages of MSC therapy for use in cartilage repair are highlighted in Table 2. While early research on MSCs shows promise for use in cartilage repair, more extensive clinical trials are necessary to

clearly demonstrate the efficacy, safety, and benefits of treating patients with osteoarthritis.

References

1. W-Dahl A, Robertsson O, Lidgren L. Surgery for knee osteoarthritis in younger patients: a Swedish Register Study. *Acta Orthop* 2010;81:161-164.
2. Meehan JP, Danielsen B, Kim SH, Jamali AA, White RH. Younger age is associated with a higher risk of early periprosthetic joint infection and aseptic mechanical failure after total knee arthroplasty. *J Bone Joint Surg Am* 2014;96:529-535.
3. Tremolada C, Beltrami G, Margri A, et al. Adipose mesenchymal stem cells and "regenerative adipose tissue graft" (Lipogems™) for musculoskeletal regeneration. *Eur J Musc Dis* 2015;3:57-67.
4. Benzi R, Marfia G, Bosetti M, et al. Microfractured lipooaspirate may help oral bone and soft tissue regeneration: a case report. *CellR4* 2015;33:e1583.
5. Banchi F, Maioli M, Leonardi E, et al. A new nonenzymatic method and device to obtain a fat tissue derivative highly enriched in pericyte-like elements by mild mechanical forces from human lipoaspirates. *Cell Transplant* 2013;22:2063-2077.
6. Tremolada C, Colombo V, Ventura C. Adipose tissue and mesenchymal stem cells: state of the art and Lipogems® technology development. *Curr Stem Cell Rep* 2016;2:304-312.
7. Hernigou P, Desroches A, Queinnee S, et al. Morbidity of graft harvesting versus bone marrow aspiration in cell regenerative therapy. *Int Orthop* 2014;9:1855-1860.
8. Bergers G, Song S. The role of pericytes in blood-vessel formation and maintenance. *Neuro-oncology* 2005;7:452-464.
9. Toghraie FS, Chenari N, Gholipour MA, et al. Treatment of osteoarthritis with infrapatellar fat pad derived mesenchymal stem cells in Rabbit. *Knee* 2011;18:71-75.
10. Ude CC, Sulaiman SB, Min-Hwei N, et al. Cartilage regeneration by chondrogenic induced adult stem cells in osteoarthritic sheep model. *PLoS One* 2014;6:e98770.
11. Koh YG, Choi YJ. Infrapatellar fat pad-derived mesenchymal stem cell therapy for knee osteoarthritis. *Knee* 2012;19:902-907.
12. Koh YG, Jo SB, Kwon OR, et al. Mesenchymal stem cell injections improve symptoms of knee osteoarthritis. *Arthroscopy* 2013;29:748-755.
13. Koh YG, Kwon OR, Kim YS, Choi YJ, Tak DH. Adipose-derived mesenchymal stem cells with microfracture versus microfracture alone: 2-year follow-up of a prospective randomized trial. *Arthroscopy* 2016;32:97-109.